



Original Article

# The effect of topical application of meloxicam on inflamed dental pulp



Jing-Yi Li, Sai-Nan Wang \*\*, Yan-Mei Dong\*

Department of Cariology and Endodontology, Peking University School and Hospital of Stomatology, Beijing, China

Received 20 October 2020; Final revision received 15 November 2020  
Available online 2 December 2020

## KEYWORDS

Dental pulp;  
Inflammation;  
Meloxicam

**Abstract** *Background/purpose:* Effective regulation of the inflammatory process is essential for pulp repair and regeneration. Meloxicam has anti-inflammatory activity in systemic administration. The purpose of this study is to observe effects of topically applied meloxicam on inflamed pulp and to explore its potential value in the treatment of pulpitis.

*Materials and methods:* The coronal pulp tissues of rat molars were stimulated with 10 mg/mL lipopolysaccharide (LPS group) and then treated with 500  $\mu\text{mol/L}$  meloxicam (meloxicam group). The untreated pulp tissues were used as the control group. After 3 h of incubation *in vitro*, the gene expression of interleukin-6 (*IL-6*) and tumour necrosis factor- $\alpha$  (*TNF- $\alpha$* ) in each group was detected by real-time RT-PCR. The pulp tissues of each group were randomly subcutaneously implanted into nude mice, and 500  $\mu\text{mol/L}$  meloxicam was injected into the subcutaneous pocket of the meloxicam group. Haematoxylin eosin staining, Masson staining and immunohistochemical staining were performed on samples after 3 days and 4 weeks retrieval, respectively.

*Results:* Compared with the LPS group, the mRNA expression levels of *TNF- $\alpha$*  and *IL-6* of the meloxicam group were significantly reduced *in vitro*. The inflammatory response and cyclooxygenase-2 expression of the meloxicam group were decreased, and osteodentin-like tissue was generated in the pulp cross section of the meloxicam group *in vivo*.

*Conclusion:* The topical application of meloxicam inhibits the inflammatory response of inflamed pulp and further promotes the formation of osteodentin-like tissues but fails to induce the formation of the pulp–dentin complex. Topically applied meloxicam has the potential to regulate pulp inflammation.

© 2020 Association for Dental Sciences of the Republic of China. Publishing services by Elsevier B.V. This is an open access article under the CC BY-NC-ND license (<http://creativecommons.org/licenses/by-nc-nd/4.0/>).

\* Corresponding author. Department of Cariology and Endodontology, Peking University School and Hospital of Stomatology, 22 Zhong-guancun South Avenue, Beijing, 100081, China.

\*\* Corresponding author. Department of Cariology and Endodontology, Peking University School and Hospital of Stomatology, 22 Zhong-guancun South Avenue, Beijing, 100081, China.

E-mail addresses: [bdkqwsn@bjmu.edu.cn](mailto:bdkqwsn@bjmu.edu.cn) (S.-N. Wang), [kqdongyanmei@bjmu.edu.cn](mailto:kqdongyanmei@bjmu.edu.cn) (Y.-M. Dong).

## Introduction

Pulp tissues are surrounded by hard dentin walls, lack effective collateral circulation, and have limited regeneration and repair ability. Caries, trauma, abrasion, etc. will cause inflammatory reactions in the dental pulp tissue. Early stage inflammation can initiate the repair and regeneration process, but uncontrolled chronic inflammation leads to irreversible pulp damage and eventually pulp necrosis.<sup>1</sup> Therefore, effective regulation of the inflammatory process is essential for pulp tissue repair.

Nonsteroid anti-inflammatory drugs (NSAIDs) inhibit the synthesis of prostaglandin (PG) and vasodilation by inhibiting cyclooxygenase (COX), thereby regulating the inflammation process. COX is a key rate-limiting enzyme for catalysing PG synthesis, and there are two isoforms. COX-1 is constitutively expressed under physiological conditions, and COX-2 can be induced under pathological conditions, such as inflammation and cancer.<sup>2</sup> Dental pulp fibroblasts and immune cells can synthesize and secrete PG and proinflammatory cytokines, such as tumour necrosis factor- $\alpha$  (TNF- $\alpha$ ), which together affect the inflammatory process and tissue destruction.<sup>3</sup> COX-2 is mainly expressed in pulpitis and is rarely found in healthy pulp, which may be an important factor leading to pulpitis.<sup>4</sup> NSAIDs are categorized into non-selective COX inhibitors, such as aspirin, and COX-2 inhibitors, such as meloxicam, which have better anti-inflammatory activity and fewer side effects in systemic administration. A clinical study showed that pre-treatment with oral NSAIDs significantly reduced the level of proinflammatory cytokines in irreversible pulpitis.<sup>5</sup> *In vivo* and *in vitro* studies demonstrated that aspirin promoted bone repair, especially in inflammatory conditions.<sup>6</sup> The systemic administration of meloxicam improved bone healing capacity in animal experiments.<sup>7,8</sup> Meloxicam promoted osteogenic differentiation of human adipose tissue-derived stromal cells *in vitro*.<sup>9</sup>

Our previous results indicated that meloxicam had a better anti-inflammatory effect than aspirin on human dental pulp cells (hDPCs) stimulated by lipopolysaccharide (LPS) and promoted the odontogenic differentiation and mineralization of hDPCs *in vitro*.<sup>10</sup> The purpose of this study was to further characterize the effects of topically applied meloxicam on inflamed pulp stimulated by LPS *in vitro* and *in vivo*.

## Materials and methods

### Acquisition of pulp tissues stimulated by LPS

All animal procedures were approved by the Animal Care Committee of Peking University (LA2019358). According to a previous study,<sup>11</sup> four-week-old Sprague–Dawley rats were sacrificed by excessive anaesthesia, and the first molars were separated under aseptic conditions. The obtained molars were cut from the tooth cervical with a surgical blade under the microscope, and the hard tissues of the crown and the pulp tissues were placed in Dulbecco's modified Eagle medium (DMEM, Gibco BRL, Gaithersburg, MD, USA). The control group was comprised of the pulp tissues without special treatment. The pulp tissues were

soaked in DMEM culture medium containing 10 mg/mL LPS (*Escherichia coli*, Sigma–Aldrich) for 1 min to stimulate the dental pulp to produce an inflammatory response and then placed in DMEM culture medium (LPS group). Another group of pulp tissues were soaked in DMEM containing 10 mg/mL LPS for 1 min and then DMEM containing 500  $\mu$ mol/L meloxicam (Bioruler, Beijing, China) (meloxicam group).

### Gene expression of TNF- $\alpha$ and IL-6 detected by real-time RT-PCR

The pulp tissues were treated as described above. The control group (n = 6) and the LPS group (n = 6) were separately placed in culture dishes containing DMEM, while the meloxicam group (n = 6) was placed in culture dishes containing 500  $\mu$ mol/L meloxicam. After 3 h cultured at 37 °C in 5% CO<sub>2</sub>, the pulp tissues were collected and ground using a TissueLyser II (Qiagen, Germantown, MD, USA). Tissue RNA was extracted using TRIzol (Invitrogen, Carlsbad, CA, USA), and reverse transcription was performed using Prime Script RT Master Mix (Perfect Real Time, TaKaRa, Bio, Otsu, Japan). Real-time RT-PCR was performed with the ABI QuantStudio 3 Real-Time PCR system using SYBR Green (TaKaRa) to detect the mRNA levels of TNF- $\alpha$  and interleukin-6 (IL-6). The mRNA levels were normalized to the mRNA level of glyceraldehyde-3-phosphate dehydrogenase (GAPDH) and analysed by the standard 2<sup>- $\Delta\Delta$ CT</sup> method.<sup>12</sup> The primers sequences used in the study were listed as below: IL-6: F, 5'-TAGCCTTCC-TACCCCAATTTCC-3'; R, 5'-TTGGTCCTTAGCCACTCCTTC-3'; GAPDH: F, 5'-GAAGGTGAAGGTCGGAGTC-3'; R, 5'-GAGATGGTGATGGGATTTC-3'; TNF- $\alpha$ : F, 5'-TGTA-GACCATGTAGTTGAGGTCA-3'; R, 5'-GCTACGACGTGGGCTA-CAG-3'.

### Subcutaneous transplantation of pulp tissues in nude mice

Male BALB/C nude mice aged 4 weeks were purchased from Beijing Vital River Laboratory Animal Technology Company Limited. After intraperitoneal injection of 30 mg/kg 0.5% pentobarbital sodium and iodophor disinfection of the skin on the back of nude mice, 3 mm transverse incisions were made in the skin near the hind legs on both sides of the back, and blunt separation of the subcutaneous tissue was performed to form the left and right sides of the pouch. Six samples in each group, for a total of 18 samples, were randomly implanted into the pouch separately. The pouches in the meloxicam group were injected with 250  $\mu$ L DMEM containing of 500  $\mu$ mol/L meloxicam. The incisions were sutured, the wounds were disinfected, and the nude mice were put back into a specific pathogen-free environment upon waking.

### Histological staining

Samples were retrieved at 3 and 4 weeks after surgery and then fixed with 4% paraformaldehyde for 24 h. After decalcification with 10% ethylene diamine tetraacetic acid for 3 weeks, the samples were dehydrated, waxed, and embedded in paraffin. Five-micrometre sections along the

long axis of the tooth were used for haematoxylin eosin (HE) staining, Masson staining (Baso Diagnostic, Inc., Zhuhai, Guangdong, China) and COX-2 immunohistochemical staining in accordance with the kit instructions.

### Statistical analysis

SPSS 24.0 software was used for statistical analysis. Gene expression in each group was analysed by a one-way ANOVA with the Bonferroni test. Statistical significance was defined as a *P*-value less than 0.05.

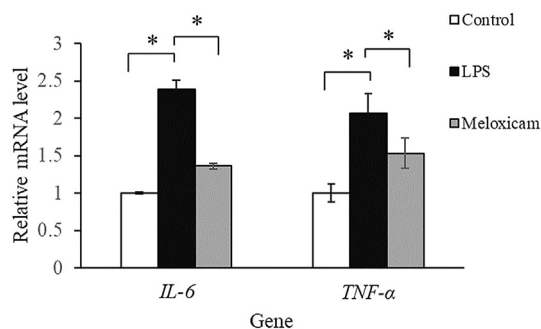
## Results

### Meloxicam inhibited the expression of *TNF- $\alpha$* and *IL-6* in inflamed pulp tissue

After 3 h of incubation of inflamed pulp tissue with meloxicam *in vitro*, the expression of *TNF- $\alpha$*  and *IL-6* was detected by real-time RT-PCR (Fig. 1). Compared with the control group, the expression levels of *TNF- $\alpha$*  and *IL-6* were significantly increased in the LPS group, which indicated that LPS stimulation induced the expression of inflammation-related genes. In the meloxicam group, the expression levels of *TNF- $\alpha$*  and *IL-6* were significantly decreased compared with those in the LPS group. The above results demonstrated that the topical application of meloxicam inhibited the gene expression of proinflammatory cytokines in inflamed pulp tissue.

### Meloxicam inhibited the inflammatory response in inflamed pulp tissue

The pulp inflammatory response was detected by HE staining after 3 days of subcutaneous implantation (Fig. 2). In the control group, the odontoblast and predentin were basically intact in the pulp tissue, and no inflammatory infiltration or vasodilation was observed (Fig. 2a and b). The pulp tissue in the LPS group showed a moderate inflammatory response, and the odontoblast and predentin layer were broken, under which was infiltration of inflammatory cells (Fig. 2c and d). The pulp tissue in the meloxicam group showed a mild inflammatory response, and the odontoblast and predentin layer were mostly complete



**Figure 1** The effects of meloxicam on the expression of *IL-6* and *TNF- $\alpha$*  in inflamed pulp tissue detected by real-time RT-PCR. The values show the mean  $\pm$  SD of *n* = 3. \*, *P* < 0.05.

with few infiltrations of inflammatory cells and vasodilation (Fig. 2e and f).

### Meloxicam inhibited the expression of COX-2 in inflamed pulp tissue

The expression level of COX-2 was detected by immunohistochemistry staining after 3 days of subcutaneous implantation (Fig. 3). In the control group, COX-2 was expressed at low levels in the odontoblast layer, and was not observed in the cell-rich zone or pulp proper (Fig. 3a and b). In the LPS group, a mount of COX-2-positive cells were detected in the odontoblast layer, cell-rich zone, and pulp proper (Fig. 3c and d). The pulp in the meloxicam group showed few COX-2-positive cells in the odontoblast layer, and the cells in the cell-rich zone and pulp proper were negative for COX-2 staining (Fig. 3e and f).

### Meloxicam induced the formation of osteodentin-like tissues in inflamed pulp tissue

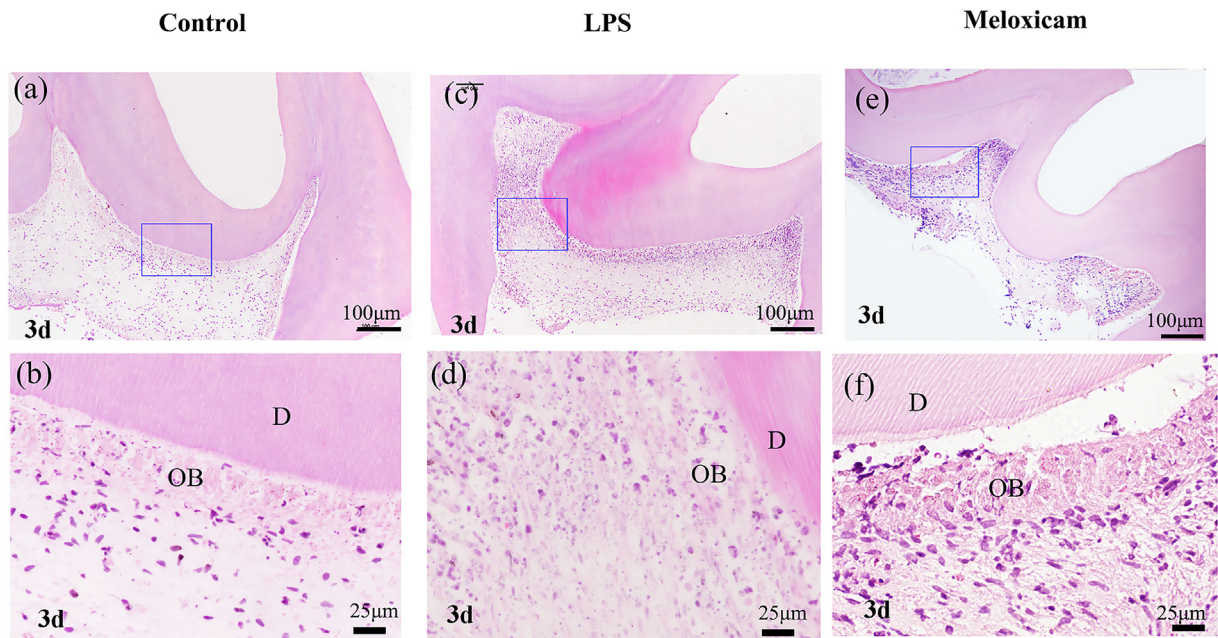
The pulp repair was detected by HE staining and Masson staining after 4 weeks of subcutaneous implantation (Figs. 4 and 5). The control group showed no inflammatory infiltration of the pulp tissue, and new blood vessels were observed. New matrix was formed under the primary dentin of the crown, and many new collagen fibres were seen in the pulp cross section (Fig. 4a and b). In the LPS group, scattered matrix was formed in the pulp core and new irregularly collagen fibres were seen in the pulp cross section (Fig. 4c and d). In the meloxicam group, new matrix was formed under the primary dentin and no infiltration of inflammation was observed. New vessels were observed in the pulp proper, and a discontinuous layer of new matrix was formed in the pulp cross section (Fig. 4e and f).

Masson staining results showed that many blue-stained collagen fibres and no mineralized matrix in the pulp cross section were observed in the control group (Fig. 5a and b). In the LPS group blue-stained collagen fibres were showed in the pulp cross section, and a mass of the blue-stained mineralized matrix wrapped around the red-stained cells was observed in the pulp proper (Fig. 5c and d). In the meloxicam group, a discontinuous layer of blue stained osteodentin-like mineralized matrix was generated in the pulp cross section (Fig. 5e and f).

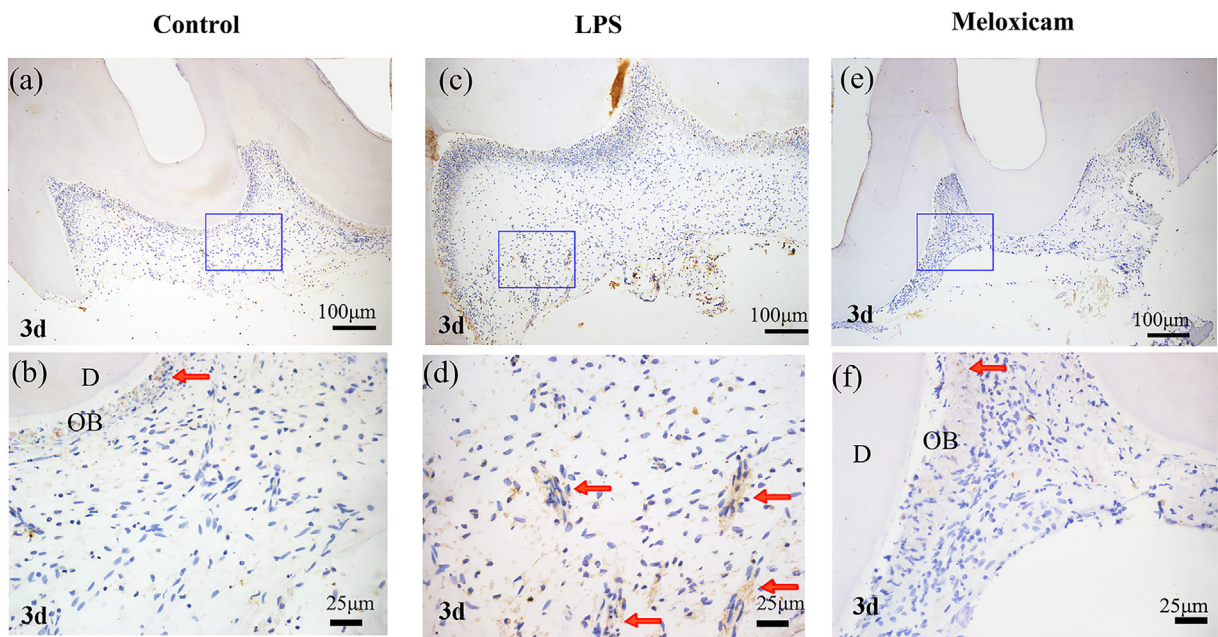
## Discussion

A dynamic balance exists between inflammation and repair. Early mild inflammation contributes to tissue repair, while excessive inflammation leads to tissue destruction. Systemic meloxicam treatment has a good curative effect in osteoarthritis and pain;<sup>13,14</sup> However, the limited blood supply of dental pulp tissue makes it difficult for systemic medication to take effect in the inflammatory front of damaged pulp. Whether the topical application of meloxicam could effectively exert its anti-inflammatory effect and promote the repair of damaged dental pulp tissue was unclear.





**Figure 2** The effect of meloxicam on the inflammatory response of pulp tissue stimulated by LPS. HE staining 3 days after implantation in nude mice. (a, b): Crown and pulp tissue implanted alone. (c, d): Crown and pulp tissue stimulated by LPS for 1 min. (e, f): Crown and pulp tissue stimulated by LPS for 1 min and treated topically with meloxicam. Abbreviations: D, dentin; OB, odontoblast.

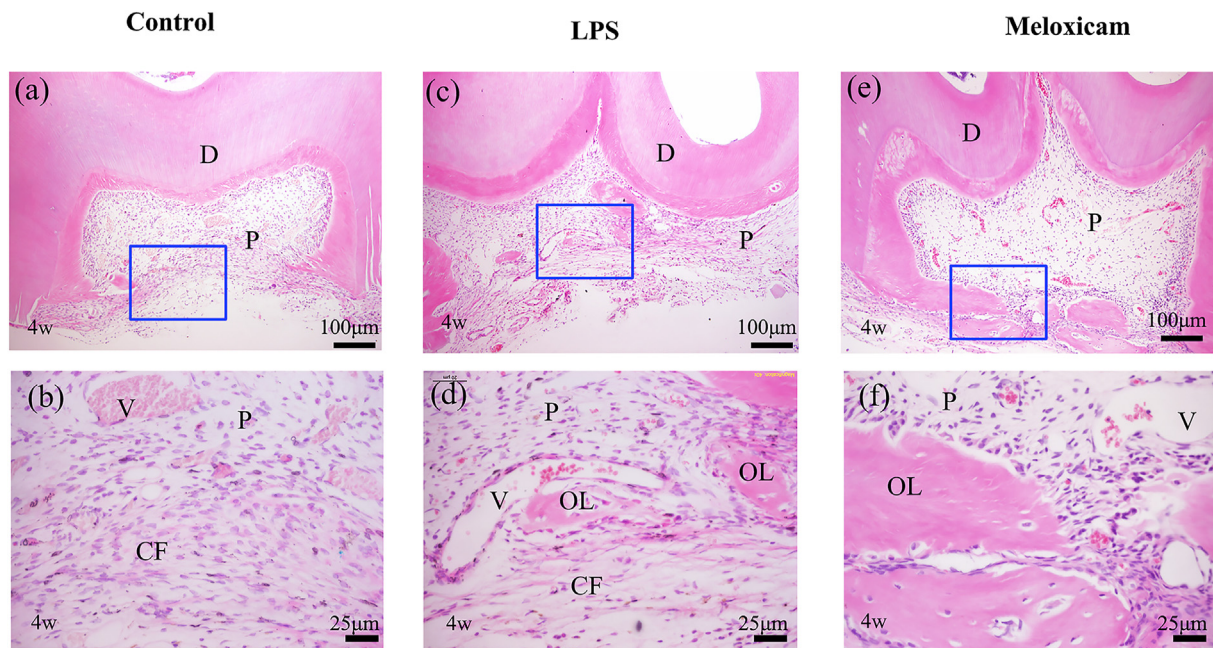


**Figure 3** The effect of meloxicam on COX-2 expression in inflamed pulp tissue stimulated by LPS. Immunohistochemical staining 3 days after implantation in nude mice. (a, b): Crown and pulp tissue implanted alone. (c, d): Crown and pulp tissue stimulated by LPS for 1 min. (e, f): Crown and pulp tissue stimulated by LPS for 1 min and treated topically with meloxicam. Abbreviations: D, dentin; OB, odontoblast. The red arrow indicates COX-2-positive cells.

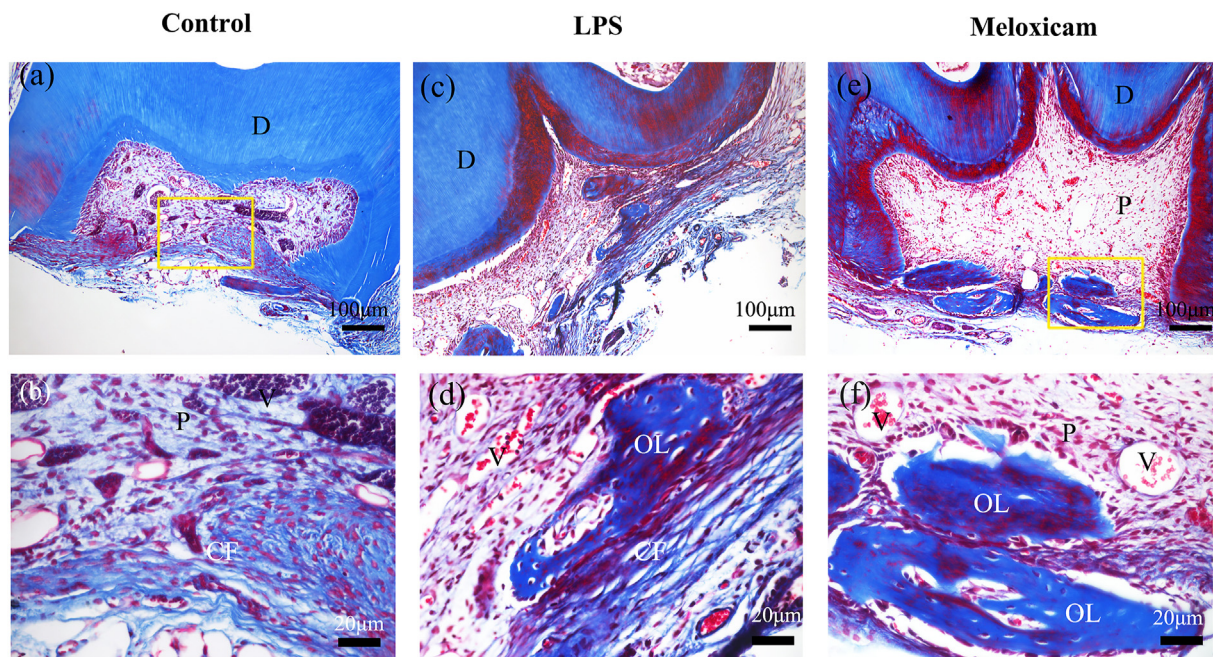
This study demonstrated that the topical application of meloxicam had good anti-inflammatory effects on moderately inflamed pulp stimulated by LPS. Subcutaneous implantation in nude mice has been used as a pre-clinical model,<sup>15</sup> and our previous studies have confirmed

this animal model to be good for observing the biological response of pulp tissue.<sup>11</sup> LPS pretreatment of dental pulp tissue is a common method to obtain inflamed pulp.<sup>16,17</sup> The proinflammatory cytokines upregulate the gene expression of matrix metalloproteinases and tissue





**Figure 4** The effect of meloxicam on inflamed pulp tissue repair stimulated by LPS. HE staining 4 weeks after implantation in nude mice. (a, b): Crown and pulp tissue implanted alone. (c, d): Crown and pulp tissue stimulated by LPS for 1 min. (e, f): Crown and pulp tissue stimulated by LPS for 1 min and treated topically with meloxicam. Abbreviations: D, dentin; OL, osteodentin-like tissues; CF, collagenous fibre; P, pulp; V, vessel.



**Figure 5** The effect of meloxicam on the mineralized matrix of inflamed pulp tissue stimulated by LPS. Masson staining 4 weeks after implantation in nude mice. (a, b): Crown and pulp tissue implanted alone. (c, d): Crown and pulp tissue stimulated by LPS for 1 min. (e, f): Crown and pulp tissue stimulated by LPS for 1 min and treated topically with meloxicam. Abbreviations: D, dentin; OL, osteodentin-like tissues; CF, collagenous fibre; P, pulp; V, vessel.

plasminogen activator, thereby further aggravating inflammation and even destroying tissue.<sup>18</sup> Meloxicam significantly downregulated the expression of the pro-inflammatory cytokines IL-6 and TNF- $\alpha$  in pulp tissues

stimulated by LPS *in vitro*. The histological results showed meloxicam alleviated the inflammatory response *in vivo*. The anti-inflammatory effect of meloxicam is related to its selective inhibition of COX-2 induced by LPS and

proinflammatory cytokines such as TNF- $\alpha$ .<sup>19</sup> This study confirmed that topically applied meloxicam inhibited the synthesis of COX-2 in inflamed pulp tissue at the histological level thus alleviating the inflammatory response of dental pulp tissue.

In this study, topically applied meloxicam induced the regeneration of a layer of osteodentin-like tissue in the cross section of the pulp, while only a small amount of irregular calcification was found inside the pulp stimulated by LPS. Meloxicam can inhibit the synthesis and secretion of prostaglandin E2 (PGE2), a subtype of PG. PGE2 has a biphasic effect on various tissues, depending on its concentration.<sup>20,21</sup> The effect of PGE2 on the differentiation and mineralization of dental pulp cells was also concentration dependent. PGE2 at 0.1  $\mu\text{mol/L}$  promoted the gene expression of alkaline phosphatase and mineralization of hDPCs, while 0.1  $\mu\text{mol/L}$  PGE2 had an inhibitory effect.<sup>22–24</sup> PGE2 at 0.25–4  $\mu\text{mol/L}$  bound to the E-series of prostaglandin receptor types (EP2) on hDPCs, activated cyclic adenosine monophosphate pathways and increased intracellular  $\text{Ca}^{2+}$  levels. Intracellular  $\text{Ca}^{2+}$  increased with increasing PGE2 in this concentration range.<sup>25,26</sup> The above studies suggested that meloxicam may regulate PGE2 by inhibiting COX-2, improved intracellular  $\text{Ca}^{2+}$  levels, and promoted mineralized tissue formation of dental pulp tissue.

The structure of mineralized tissue induced by meloxicam in pulp tissue was an osteodentin-like structure without dentinal tubule, similar to the mineralized barrier induced by direct pulp capping with calcium hydroxide.<sup>27</sup> This result indicated that meloxicam may promote mineralization but lack the ability to induce the formation of pulp–dentin complex. A previous study demonstrated that COX-2 was involved in enamel maturation and the inhibition of COX-2 could inhibit the formation of tooth enamel.<sup>28</sup> PGE2 also affected the maturation of mineralization.<sup>29</sup> The inhibitory effect of meloxicam on COX-2 and the regulation of PGE2 may be related to the maturation of odontogenic mineralization, which requires further investigation.

In conclusion, the topical application of meloxicam inhibits the inflammatory response of inflamed pulp and further promotes the formation of osteodentin-like tissues but fails to induce the formation of the pulp–dentin complex. Topically applied meloxicam has the potential to regulate pulp inflammation.

## Declaration of competing interest

The authors have no conflicts of interest relevant to this article.

## Acknowledgements

This study was supported by the National Natural Science Foundation of China (81700953, 51372005, and 81870753).

## References

- Goldberg M, Njeh A, Uzunoglu E. Is pulp inflammation a prerequisite for pulp healing and regeneration? *Mediat Inflamm* 2015;2015:347649.
- Smith WL, DeWitt DL, Garavito RM. Cyclooxygenases: structural, cellular, and molecular biology. *Annu Rev Biochem* 2000; 69:145–82.
- Nakanishi T, Matsuo T, Ebisu S. Quantitative analysis of immunoglobulins and inflammatory factors in human pulpal blood from exposed pulps. *J Endod* 1995;21:131–6.
- Chang YC, Huang FM, Yang SF, et al. Induction of cyclooxygenase-2 mRNA and protein expression in human pulp cells stimulated with black-pigmented *Bacteroides*. *J Endod* 2003;29:240–3.
- Nguyen V, Chen YW, Johnson JD, Paranjpe A. In vivo evaluation of effect of preoperative ibuprofen on proinflammatory mediators in irreversible pulpitis cases. *J Endod* 2020;9:1210–6.
- Cao Y, Xiong J, Mei S, et al. Aspirin promotes bone marrow mesenchymal stem cell-based calvarial bone regeneration in mini swine. *Stem Cell Res Ther* 2015;6:210.
- Yamasaki MC, Nejaim Y, Roque-Torres GD, Freitas DQ. Meloxicam as a radiation-protective agent on mandibles of irradiated rats. *Braz Dent J* 2017;28:249–55.
- Kirschneck C, Meier M, Bauer K, Proff P, Fanghanel J. Meloxicam medication reduces orthodontically induced dental root resorption and tooth movement velocity: a combined in vivo and in vitro study of dental-periodontal cells and tissue. *Cell Tissue Res* 2017;368:61–78.
- Hadjicharalambous C, Alexaki VI, Alpantaki K, Chatzinikolaïdou M. Effects of NSAIDs on the osteogenic differentiation of human adipose tissue-derived stromal cells. *J Pharm Pharmacol* 2016;68:1403–8.
- Li JY, Wang SN, Dong YM. Anti-inflammatory and repaired effects of non-steroidal anti-inflammatory drugs on human dental pulp cells. *Beijing Da Xue Xue Bao Yi Xue Ban* 2020;52: 24–9 [In Chinese, English abstract].
- Wang S, Gao X, Gong W, Zhang Z, Chen X, Dong Y. Odontogenic differentiation and dentin formation of dental pulp cells under nanobioactive glass induction. *Acta Biomater* 2014;10: 2792–803.
- Pfaffl MW. A new mathematical model for relative quantification in real-time RT-PCR. *Nucleic Acids Res* 2001;29.
- Yocum D, Fleischmann R, Dalgin P, Caldwell J, Hall D, Roszko P. Safety and efficacy of meloxicam in the treatment of osteoarthritis: a 12-week, double-blind, multiple-dose, placebo-controlled trial. the meloxicam osteoarthritis investigators. *Arch Intern Med* 2000;160:2947–54.
- Pollak RA, Gottlieb IJ, Hakakian F, et al. Efficacy and safety of intravenous meloxicam in patients with moderate-to-severe pain following bunionectomy: a randomized, double-blind, placebo-controlled trial. *Clin J Pain* 2018;34:918–26.
- Kelland LR. Of mice and men: values and liabilities of the athymic nude mouse model in anticancer drug development. *Eur J Canc* 2004;40:827–36.
- Huang J, Lv Y, Fu Y, et al. Dynamic regulation of delta-opioid receptor in rat trigeminal ganglion neurons by lipopolysaccharide-induced acute pulpitis. *J Endod* 2015;41: 2014–20.
- Renard E, Gaudin A, Bienvenu G, et al. Immune cells and molecular networks in experimentally induced pulpitis. *J Dent Res* 2016;95:196–205.
- Chang YC, Yang SF, Hsieh YS. Regulation of matrix metalloproteinase-2 production by cytokines and pharmacological agents in human pulp cell cultures. *J Endod* 2001;27: 679–82.
- Chang YC, Yang SF, Huang FM, Liu CM, Tai KW, Hsieh YS. Proinflammatory cytokines induce cyclooxygenase-2 mRNA and protein expression in human pulp cell cultures. *J Endod* 2003; 29:201–4.
- Tang L, Loutzenhiser K, Loutzenhiser R. Biphasic actions of prostaglandin E(2) on the renal afferent arteriole : role of EP(3) and EP(4) receptors. *Circ Res* 2000;86:663–70.



21. Kleiveland CR, Kassem M, Lea T. Human mesenchymal stem cell proliferation is regulated by PGE<sub>2</sub> through differential activation of cAMP-dependent protein kinase isoforms. *Exp Cell Res* 2008;314:1831–8.
22. Samoto H, Shimizu E, Matsuda-Honjyo Y, et al. Prostaglandin E<sub>2</sub> stimulates bone sialoprotein (BSP) expression through cAMP and fibroblast growth factor 2 response elements in the proximal promoter of the rat BSP gene. *J Biol Chem* 2003;278:28659–67.
23. Choudhary S, Wadhwa S, Raisz LG, Alander C, Pilbeam CC. Extracellular calcium is a potent inducer of cyclo-oxygenase-2 in murine osteoblasts through an ERK signaling pathway. *J Bone Miner Res* 2003;18:1813–24.
24. Lorencetti-Silva F, Pereira P, Meirelles A, Faccioli LH, Paula-Silva F. Prostaglandin E<sub>2</sub> induces expression of mineralization genes by undifferentiated dental pulp cells. *Braz Dent J* 2019;30:201–7.
25. Chang MC, Chen YJ, Tai TF, et al. Cytokine-induced prostaglandin E<sub>2</sub> production and cyclooxygenase-2 expression in dental pulp cells: downstream calcium signalling via activation of prostaglandin EP receptor. *Int Endod J* 2006;39:819–26.
26. Chang MC, Lin SI, Lin LD, et al. Prostaglandin E<sub>2</sub> Stimulates EP<sub>2</sub>, Adenylate Cyclase, Phospholipase C, and intracellular calcium release to mediate cyclic adenosine monophosphate production in dental pulp cells. *J Endod* 2016;42:584–8.
27. Didilescu AC, Cristache CM, Andrei M, Voicu G, Perlea P. The effect of dental pulp-capping materials on hard-tissue barrier formation: a systematic review and meta-analysis. *J Am Dent Assoc* 2018;149:903–17.
28. Serna MC, Perez SA, Solano F, Castells MT, Vicente A, Ortiz RA. Effect of antibiotics and NSAIDs on cyclooxygenase-2 in the enamel mineralization. *Sci Rep* 2018;8:4132.
29. Suzuki H, Ohshima N, Tatei K, Taniguchi T, Sato S, Izumi T. The role of autonomously secreted PGE<sub>2</sub> and its autocrine/paracrine effect on bone matrix mineralization at the different stages of differentiating MC3T3-E1 cells. *Biochem Biophys Res Commun* 2020;524:929–35.