

Comparative efficacy and safety of radiotherapy/cetuximab versus radiotherapy/chemotherapy for locally advanced head and neck squamous cell carcinoma patients: a systematic review of published, primarily non-randomized, data

Mei Mei, Yu-Huan Chen , Tian Meng, Ling-Han Qu, Zhi-Yong Zhang and Xiao Zhang

Abstract

Background: Cetuximab (CTX) has been approved to be administered concurrently with radiotherapy (RT) to treat locally advanced head and neck squamous cell carcinoma (HNSCC). The aim of this study was to assess the efficacy and safety of concurrent CTX with RT (ExRT).

Method: The *PubMed*, *Cochrane Library*, *EMBASE* databases were systematically searched to find relevant articles. The combined hazard ratio (HR), risk ratio (RR) and 95% confidence interval were calculated to assess the efficacy and safety of ExRT in contrast to concurrent platinum-based chemotherapy with RT (ChRT).

Results: In total, 32 articles with 4556 patients were included. The pooled HRs indicated that ExRT achieved an unfavorable overall survival (HR: 1.86, $p < 0.0001$), disease-specific survival (HR: 2.58, $p = 0.002$), locoregional control (HR: 1.94, $p < 0.00001$), and progression-free survival (HR: 2.04, $p = 0.003$) compared with ChRT for locally advanced HNSCC patients. In human papillomavirus-positive patient subgroups, ExRT showed inferior disease-specific survival (HR: 2.55, $p = 0.009$) and locoregional control (HR: 2.27, $p < 0.0001$) in contrast to ChRT. Additionally, ExRT increased the occurrence of mucositis (RR: 1.17, $p < 0.005$), skin toxicity (RR: 6.26, $p < 0.00001$), and infection (RR: 2.27, $p = 0.04$) compared with non-CTX groups (ChRT and RT), and was associated with lower incidence of anemia (RR: 0.35, $p = 0.009$), leukocytopenia (RR: 0.17, $p < 0.0001$), neutropenia (RR: 0.06, $p < 0.0001$), nausea/vomiting (RR: 0.23, $p < 0.0001$), and renal toxicity (RR: 0.14, $p = 0.007$).

Conclusion: ChRT should remain the standard treatment for locally advanced HNSCC patients. ExRT was recognized as an effective alternative treatment for locally advanced HNSCC patients who experienced unbearable toxicities caused by non-CTX treatments.

Keywords: cetuximab, chemoradiotherapy, head and neck cancer, platinum, radiotherapy

Received: 20 April 2020; revised manuscript accepted: 28 October 2020.

Introduction

Head and neck cancer encompasses malignancies of the oral cavity, oropharynx, hypopharynx, and larynx, which remains a significant cause of morbidity and mortality and ranks the seventh most common cancer worldwide in 2018.¹ Over 90% patients are

classified as head and neck squamous cell carcinoma (HNSCC), and the landscape of HNSCC treatment has evolved over the past decade. Approximately 30–40% of HNSCC patients present with early stage (stage I/II), which is commonly curable with surgery alone or in combination with

Ther Adv Med Oncol

2020, Vol. 12: 1–18

DOI: 10.1177/
1758835920975355

© The Author(s), 2020.
Article reuse guidelines:
sagepub.com/journals-
permissions

Correspondence to:

Zhi-Yong Zhang
First Clinical Division,
Peking University
School and Hospital
of Stomatology,
National Engineering
Laboratory for Digital and
Material Technology of
Stomatology, and Beijing
Key Laboratory of Digital
Stomatology, No. 37A
Xishiku Road, Xichen
District, Beijing, 100034,
China

zhangzybjmu@126.com

Xiao Zhang
First Clinical Division,
Peking University
School and Hospital
of Stomatology,
National Engineering
Laboratory for Digital and
Material Technology of
Stomatology, and Beijing
Key Laboratory of Digital
Stomatology, No. 37A
Xishiku Road, Xichen
District, Beijing, 100034,
China

zhangxiao196533@outlook.com

Mei Mei
Yu-Huan Chen
Tian Meng
First Clinical Division,
Peking University
School and Hospital
of Stomatology,
National Engineering
Laboratory for Digital and
Material Technology of
Stomatology, and Beijing
Key Laboratory of Digital
Stomatology, Beijing,
China

Ling-Han Qu
Department of Oral and
Maxillofacial Surgery,
Peking University
School and Hospital
of Stomatology,
National Engineering
Laboratory for Digital and
Material Technology of
Stomatology, and Beijing
Key Laboratory of Digital
Stomatology, Beijing,
China

radiotherapy (RT).² More than 60% of HNSCC patients are diagnosed with locally advanced stage (stage III/IV), which has a high risk of local recurrence with a poor prognosis.^{3,4} For locally advanced stage HNSCC, the established standard treatment is concurrent platinum-based chemotherapy with RT (ChRT), which further improves the survival rate and life quality of patients than RT alone.^{5,6} However, the usage of platinum-based chemotherapy especially with high-dose cisplatin could be accompanied by severe acute toxicities such as nephrotoxicity, hematologic toxicity, and nausea/vomiting during the early stage, and late toxicities in the long term such as severe difficulty in swallowing or feeding tube dependency.⁷ Therefore, there is an urgent need for discovering new treatments to further improve the prognosis and tolerance for locally advanced HNSCC.

Epidermal growth factor receptor (EGFR), a 170-kDa polypeptide, belongs to a member of the Her family of tyrosine kinase receptors and regulates critical cell functions such as proliferation, migration, differentiation, and survival of cancer cells.⁸ As a biological marker abnormally elevated in some epithelial malignancies such as esophagus cancer, colorectal cancer, and non-small cell lung cancer, EGFR emerges as an essential target for new therapeutic strategies.^{9,10} Cetuximab (CTX) is a monoclonal antibody derived from the murine antibody M225, and it specifically binds to EGFR, then inhibits its downstream signaling pathway. The potential mechanisms of CTX used in malignancies involve inhibiting cell cycle at G1 phase and enhancing radiation-induced apoptosis.⁹ Currently, CTX has been approved by the United States Food and Drug Administration (FDA) to improve patient outcomes in many cancers, such as metastatic colorectal cancer.¹¹

In HNSCC, EGFR expression is confirmed to be considerably increased, compared with the adjacent normal tissue, suggesting EGFR as a potentially important target.¹² In 2006, Bonner *et al.* conducted a randomized controlled trial (RCT) which compared CTX plus concomitant RT (ExRT) with RT alone for HNSCC. Their preliminary results demonstrated a 13% improvement in locoregional control (LRC) and a 10% improvement in three-year overall survival (OS) in ExRT group without increasing the common toxic effects associated with radiotherapy, and ExRT exhibited a 9.2% improvement in five-year OS in contrast to RT.¹³ As a consequence, ExRT

was approved by the FDA to be used in locally advanced HNSCC patients receiving primary radiotherapy or in recurrent/metastatic HNSCC patients.¹⁴

Because of lacking adequate rationale for the superiority of ExRT, the number of studies comparing ExRT with ChRT in locally advanced HNSCC has been growing, but different conclusions have been drawn, especially comparing ExRT with ChRT. By assessing the efficacy outcomes, some trials approved the superiority of ChRT compared with ExRT in HNSCC. Koutcher *et al.* demonstrated that ChRT achieved better LRC, failure-free survival, and OS than ExRT.¹⁵ Ley *et al.* confirmed that disease-specific survival (DSS) was superior in the patients receiving ChRT.¹⁶ Peddi *et al.* found that the two-year progression-free survival (PFS) in ChRT group was significantly better than that in ExRT group.¹⁷ Some studies came to the conclusion that there was no difference between ChRT and ExRT regarding the efficacy outcomes in HNSCC. Ye *et al.* confirmed similar OS comparing ChRT and ExRT, Strom *et al.* found no difference in LRC, distant metastasis rate, and OS between groups.^{18,19} For elderly patients ≥ 65 years old, Huang *et al.* demonstrated that there was no difference between ChRT and ExRT for LRC, DDS, and OS.²⁰

Therefore, it is necessary to conduct an updated systematic review by retrieving more recent publications to clarify the pooled effects of ExRT for locally advanced HNSCC. In the present study, we summarize published data to evaluate the therapeutic effects and safety of ExRT in contrast to ChRT.

Materials and methods

Study identification and searching strategy

This study complies with the Preferred Reporting Item for Systematic Reviews and Meta-Analyses guidelines.²¹ The *PubMed*, *Cochrane Library*, and *EMBASE* databases were systematically searched to find relevant articles using the following search terms as keywords in titles and abstracts: (“cetuximab” and “radiotherapy”) and (“head and neck cancer” or “head and neck tumor” or “head and neck carcinoma” or “HNSCC”). The search was updated until June 2020. In the search process, we used MeSH keywords and broader search terms to search in order to collect all articles

related to this topic, and we provide the electronic search strategy for the *PubMed* database in Supplemental material file 1 online. We also checked references cited in included articles manually to find the relevant articles.

Inclusion and exclusion criteria

The following inclusion criteria were adopted based on the following PICOS criteria: (P) Patients: patients with locally advanced stage III/IV HNSCC. (I) Intervention: patients received ExRT. (C) Comparator: patients receiving ChRT or RT (only for analyzing the safety of ExRT). (O) Outcomes: the existing literature provided with sufficient data for estimating the following outcomes: OS, DSS, LRC, PFS, metastasis-free survival (MFS), and grade 3/4/5 toxicities. (S) Study design: RCT, prospective cohort study, retrospective cohort study.

The following studies were excluded: (1) non-human study; (2) the essential information was not sufficiently complete to extract the data for meta-analysis; (3) review, letter, and case report. The flow chart of searches is shown in Figure 1.

Data extraction and analysis

Two authors used pre-designed tables to extract data from the studies, which included the following items: first author, publication year, the population (country), study design, age, gender, grouping, the total number of patients with HNSCC in ExRT group and control group, follow-up years, OS [hazard ratio (HR), 95% confidence interval (CI)], DSS (HR, 95% CI), LRC (HR, 95% CI), PFS (HR, 95% CI), MFS (HR, 95% CI) as well as a range of grade 3/4/5 toxicities [risk ratio (RR), 95% CI]. Any divergences between authors concerning the eligibility of a study were resolved by consulting a third author or by consensus.

Statistical methods

Most studies provided log-rank curves of OS, DSS, LRC, PFS, and MFS, but did not directly offer HR data. We calculated HR by using log-rank curve point-taking method. For OS, we also combined the results of multivariate Cox regression analysis with HR to analyze the risk factors for it. The RR of adverse events from included studies was analyzed between groups. All extracted data

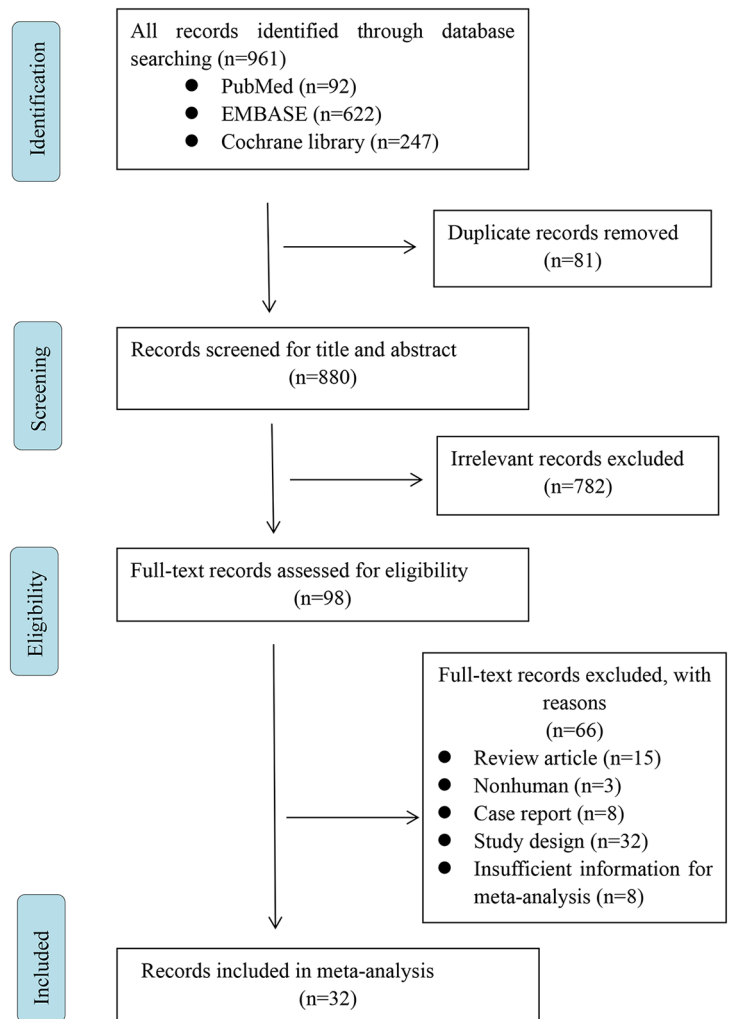


Figure 1. Flowchart of study selection.

were entered into RevMan 5.3 (Cochrane Collaboration's Information Management System) for statistical analysis. The heterogeneity test between studies was evaluated by I^2 statistics and Q test. If $I^2 \geq 50\%$, the eligible studies were considered to be heterogeneous; in contrast, if $I^2 < 50\%$, the studies were considered to be homogeneous. The fixed-effects model was used if homogeneity was found. The random-effects model was used if heterogeneity was found. p values were two-tailed, and all p values less than 0.05 were considered statistically significant.

Quality assessment

We used the Newcastle–Ottawa Scale (NOS) for assessing the quality of prospective cohort studies. NOS is suitable for evaluating case–control

studies and cohort studies. It evaluates cohort studies and case–control studies with three blocks and eight items, including population selection, comparability, exposure evaluation or outcome evaluation. All investigators independently assessed the quality and bias of the study. The differences were resolved by consensus or by arbitration by the third investigator.

Assessment of risk of bias

Publication bias was detected by funnel plots, and Begg's and Egger's tests using Stata software version 14.0, with a p value of less than 0.05 suggesting publication bias. According to the method proposed by Peters,²² the asymmetry of the funnel plot evaluating the overall efficacy indicated the studies missing in areas of statistical non-significance, which might be due to publication bias.

Results

Eligible studies and description of studies

As seen in Figure 1, at the initial search stage, a total of 961 articles were identified from three databases. Following screening of the titles and abstracts, we excluded duplicates and irrelevant articles, leaving 98 articles. Later, through reading the full text, 66 articles were excluded with reasons: review article ($n=15$), non-human study ($n=3$), case report ($n=8$), study design ($n=32$), and insufficient information for meta-analysis ($n=8$). Finally, 32 articles with a total sample size of 4556 were included. The main characteristics of the studies are shown in Table 1. To assess the efficacy of ExRT compared with ChRT for locally advanced HNSCC patients, we included 25 trials.^{15–20,23–41} In human papillomavirus (HPV)-positive subgroups which compared the efficacy of ExRT with that of ChRT, six trials were included.^{16,34,39,40,42,43} The subgroups comparing ExRT with RT included five studies, and the data were retrieved only for analyzing the safety of ExRT in contrast to ChRT/RT for locally advanced HNSCC patients.

Survival outcomes of ExRT versus ChRT for locally advanced HNSCC patients

OS. Nineteen studies reported the OS of HNSCC patients receiving ExRT in contrast to ChRT. Using a random-effects model according to the

test of heterogeneity ($p=0.001$; $I^2=57\%$), the HR of OS was 1.86 (95% CI: 1.38–2.50, $p<0.0001$; Figure 2A), indicating that ChRT achieved better OS than ExRT.

DSS. Four studies reported the DSS of HNSCC patients receiving ExRT compared with ChRT, and the data were analyzed with a fixed-effects model according to the test of heterogeneity ($p=0.64$; $I^2=0\%$). Results showed that the HR of DSS was 2.58 (95% CI: 1.41–4.73, $p=0.002$; Figure 2B), indicating that ChRT was associated with a significantly better DSS than was ExRT.

LRC. Eight studies investigated the LRC of HNSCC patients receiving ExRT compared with ChRT. Using a fixed-effects model according to the test of heterogeneity ($p=0.31$; $I^2=16\%$), the HR of LRC was 1.94 (95% CI: 1.48–2.55, $p<0.00001$; Figure 2C), suggesting that ChRT achieved a better LRC than did ExRT.

PFS. Eight studies reported the PFS of HNSCC patients receiving ExRT in contrast to ChRT, and the data were analyzed with a random-effects model according to the test of heterogeneity ($p=0.002$; $I^2=70\%$). Results showed that the HR of PFS was 2.04 (95% CI: 1.26–3.29, $p=0.003$; Figure 2D), indicating that ChRT was associated with a significantly better PFS than was ExRT.

MFS. Three studies reported the MFS of HNSCC patients receiving ExRT in contrast to ChRT. Using a fixed-effects model according to the test of heterogeneity ($p=0.89$; $I^2=0\%$), the pooled HR of MFS was 1.04 (95% CI: 0.41–2.62, $p=0.94$; Figure 2E), suggesting that there was no difference in MFS of HNSCC patients between ExRT and ChRT.

Multivariate analysis by Cox proportional hazards model on OS. To confirm whether the OS of HNSCC patients was associated with ExRT treatment in contrast to ChRT, we made multivariate analysis by Cox proportional hazards model, which included the clinical, tumor, and therapeutic variables extracted from six studies. Using a fixed-effects model according to the test of heterogeneity ($p=0.18$; $I^2=34\%$), the pooled HR of OS was 1.63 (95% CI: 1.17–2.26, $p=0.004$; Figure 3), indicating that ExRT was a risk factor for OS of locally advanced HNSCC patients in contrast to ChRT.

Table 1. Characteristics of included studies.

Study	Study design	Comparison (investigation versus control)	Chemotherapy	Age		Sample size	Country	Follow-up, months	
				Investigation	Control			Investigation	Control
Beijer <i>et al.</i> ²⁶	Retrospective cohort	ExRT versus ChRT	Cisplatin (100 mg/m ²) was administered intravenously at days 1, 22, and 43 of RT. In the case of severe nephrotoxicity (creatinine clearance <40 mL/min) or ototoxicity during treatment, cisplatin was replaced by carboplatin.	Primary: 64 (42–76) Adjuvant: 56 (51–70)	Primary: 56 (22–68) Adjuvant: 59 (39–69)	ExRT: 32 ChRT: 93	Netherlands	Primary: 29 (11–41) Adjuvant: 15 (14–20)	Primary: 24 (10–45) Adjuvant: 15 (11–42)
Bibault <i>et al.</i> ²⁷	Prospective cohort	ExRT versus ChRT	Most of the patients received cisplatin and six patients received carboplatin.	89.7% patients: >55	96.6% patients: >55	ExRT: 29 ChRT: 29	France	20.6 (median value)	20.6 (median value)
Caudell <i>et al.</i> ²⁸	Retrospective cohort	ExRT versus ChRT	Platinum-based ChRT: in 63 patients, chemotherapy consisted of a platinum doublet (in 42 patients platinum–taxol, and in 21 platinum–5-fluorouracil), and in 40 a platinum alone.	54 (34–80)	55 (23–78)	ExRT: 29 ChRT: 103	USA	83 (median value)	53 (median value)
Dornoff <i>et al.</i> ²⁹	Retrospective cohort	ExRT versus ChRT	In combination with cisplatin, 5-fluorouracil (600 mg/m ²) was applied to 23 of the 33 patients treated with chemotherapy (70%).	60.6% patients: >62.3	60.6% patients: <62.3	ExRT: 33 ChRT: 33	Germany	18.3 (mean value)	18.3 (mean value)
Hu <i>et al.</i> ³⁰	Retrospective cohort	ExRT versus ChRT	Split-dose cisplatin-based chemotherapy.	78 (46–94)	55 (33–74)	ExRT: 54 ChRT: 116	Taiwan, China	13.05 (0.93–36.00)	19.11 (2.67–36.00)
Huang <i>et al.</i> ²⁰	Retrospective cohort	ExRT versus ChRT	Chemotherapy was chosen at the discretion of the treating medical oncologist. Cisplatin was given at a bolus dose of 100 mg/m ² every 21 days during RT, with a maximum of three doses. Carboplatin was given weekly at an area under the curve of 1.5. Cisplatin and 5-fluorouracil were given at 100 mg/m ² on day 1 and 1000 mg/m ² on days 1–4, respectively, every 3 weeks for two courses.	77 (47–85)	58 (36–86)	ExRT: 31 ChRT: 62	USA	10.8 (0–72.3)	26.4 (0–99.6)
Koutcher <i>et al.</i> ¹⁵ , Riaz <i>et al.</i> ³⁸	Retrospective cohort	ExRT versus ChRT	Cisplatin was administered at a planned dose of 100 mg/m ² (50 mg/m ² × 2 days was allowed). We intended to administer cisplatin every 3 weeks, with a maximum of three doses.	59.2% patients: <71	94.4% patients: <71	ExRT: 49 ChRT: 125	USA	47 (median value)	47 (median value)

(Continued)

Table 1. (Continued)

Study	Study design	Comparison (investigation versus control)	Chemotherapy	Age		Sample size	Country	Follow-up, months	
				Investigation	Control			Investigation	Control
Law <i>et al.</i> ³⁷	Retrospective cohort	ExRT versus ChRT	Weekly cisplatin (40 mg/m ²).	67 (59–71)	65 (59–68.5)	ExRT: 21 ChRT: 21	Hong Kong, China	16 (median value)	21 (median value)
Levy <i>et al.</i> ³¹ , Ou <i>et al.</i> ³⁹	Retrospective cohort	ExRT versus ChRT	Cisplatin was administered at a planned dose of 100 mg/m ² every 3 weeks on days 1, 22, and 43, with a maximum of three cycles.	60 (42–81)	58 (36–79)	ExRT: 71 ChRT: 194	France	29 (median value)	29 (median value)
Ley <i>et al.</i> ¹⁶	Retrospective cohort	ExRT versus ChRT	Scheduled cisplatin (100 mg/m ² on days 1, 22, and 43 of RT).	62 (46–86)	55 (35–78)	ExRT: 29 ChRT: 18	USA	18 (4–54)	35 (7–64)
Magrini <i>et al.</i> ³² , Buglione <i>et al.</i> ⁴⁰	RCT	ExRT versus ChRT	Concomitant cisplatin was started simultaneously with RT at a dose of 40 mg/m ² intravenously once per week for the duration of RT.	61 (44–80)	67.5 (36–77)	ExRT: 35 ChRT: 35	Italy	19.3 (0–48)	20.6 (0–39)
Murakami <i>et al.</i> ³³	Retrospective cohort	ExRT versus ChRT	Administration of first cisplatin (80 mg/m ²) was on the same day as RT start, followed by triweekly cisplatin (80 mg/m ²) administration.	70 (54–85)	69 (51–73)	ExRT: 15 ChRT: 15	Japan	11	11
Onita <i>et al.</i> ³⁴	Retrospective cohort	ExRT versus ChRT	High-dose cisplatin (100 mg/m ² triweekly)	70 (40–86)	57 (33–78)	ExRT: 40 ChRT: 251	USA	40 (median value)	40 (median value)
Peddi <i>et al.</i> ¹⁷	Retrospective cohort	ExRT versus ChRT	Cisplatin was administered at a dose of 100 mg/m ² intravenously every 3 weeks for a maximum of three doses.	61 (mean value)	55 (mean value)	ExRT: 24 ChRT: 45	USA	11.48 (median value)	23.9 (median value)
Rawat <i>et al.</i> ³⁵	Retrospective cohort	ExRT versus ChRT	Weekly concurrent cisplatin chemotherapy (40 mg/m ²) along with RT.	61 (32–70)	53 (28–65)	ExRT: 23 ChRT: 30	India	25.9 (3–78.6)	32.9 (4.2–95.3)
Sakashita <i>et al.</i> ³⁶	Retrospective cohort	ExRT versus ChRT	Cisplatin was administered at a dose of 40 mg/m ² on weeks 1, 2, 3, 5, 6, and 7 of the RT.	75 (58–81)	61 (41–75)	ExRT: 14 ChRT: 29	Japan	NA	NA
Shapiro <i>et al.</i> ²³	Retrospective cohort	ExRT versus ChRT	259 patients received cisplatin; 52 patients received d 5-fluorouracil/carboplatin.	59.2% patients: <71	95.4% patients: <71	ExRT: 49 ChRT: 311	USA	53.1 (5.3–93.0)	53.1 (5.3–93.0)
Strojan <i>et al.</i> ²⁴	Prospective cohort	ExRT versus ChRT	Concomitant chemotherapy with cisplatin (30 mg/m ² /per week).	58 (45–63)	57 (42–75)	ExRT: 18 ChRT: 21	Slovenia	46.8 (43.2–60)	46.8 (43.2–60)
Strom <i>et al.</i> ¹⁹	Retrospective cohort	ExRT versus ChRT	Cisplatin at 75–100 mg/m ² given every 3 weeks for 2–3 cycles.	62 (39–85)	58 (28–76)	ExRT: 38 ChRT: 241	USA	27 (4–85)	27 (4–85)

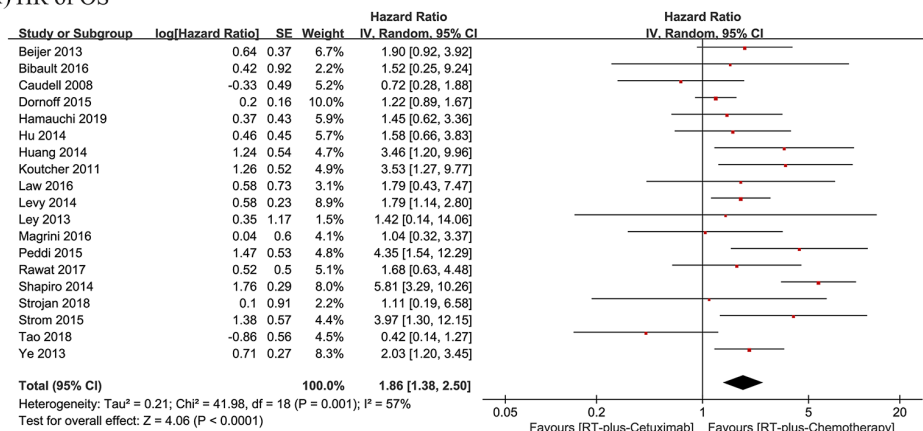
(Continued)

Table 1. (Continued)

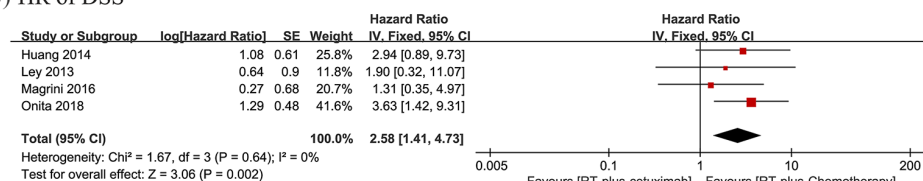
Study	Study design	Comparison (investigation versus control)	Chemotherapy	Age		Sample size	Country	Follow-up, months	
				Investigation	Control			Investigation	Control
Tao <i>et al.</i> ²⁵	RCT	ExRT versus ChRT	Patients received concomitant hydroxyurea (1.5 g/day orally) and continuous infusion fluorouracil (800 mg/m ² per day).	NA	NA	ExRT: 27 ChRT: 26	Switzerland	36 (31–43)	36 (31–43)
Ye <i>et al.</i> ¹⁸	Retrospective cohort	ExRT versus ChRT	Concurrent cisplatin was delivered per protocol as in-patient 100 mg/m ² on days 1, 22, and 43, out-patient 75 mg/m ² on days 1–3 and 29–31 or less frequently as out-patient 40 mg/m ² weekly.	62 (40–89)	57 (29–74)	ExRT: 87 ChRT: 262	Canada	16 (median value)	20 (median value)
Hamauchi <i>et al.</i> ⁴¹	Retrospective cohort	ExRT versus ChRT	Concurrent carboplatin was administered triweekly or once weekly with conventionally fractionated RT.	75 (56–83)	74 (54–82)	ExRT: 18 ChRT: 29	Japan	53.6 (25.5–62.5)	60 (13.2–94.2)
Mehanna <i>et al.</i> ⁴³	RCT (HPV-positive patients)	ExRT versus ChRT	62 (38%) patients received all three cycles of cisplatin, 83 (51%) received two cycles, and 16 (10%) received one cycle. Of those who received one or two cycles, nine received one or two doses of carboplatin instead.	57 (51–64)	56.5 (52–62)	ExRT: 168 ChRT: 166	Ireland, Netherlands, and the UK	25.9 (median value)	25.9 (median value)
Gillison <i>et al.</i> ⁴²	RCT (HPV-positive patients)	ExRT versus ChRT	In the cisplatin group, chemotherapy was given per protocol in 88% (<i>n</i> = 356). Both cycles of cisplatin were delivered in a large majority (93%; <i>n</i> = 377). Mean dose received was 184.7 mg/m ² .	58 (52–63)	58 (52–63)	ExRT: 399 ChRT: 406	America	54 (median value)	54 (median value)
Bonner <i>et al.</i> ^{13,44,45}	RCT	ExRT versus RT	—	56 (34–81)	58 (35–83)	ExRT: 211 RT: 213	USA	54 (median value)	54 (median value)
Heron <i>et al.</i> ⁴⁶	Retrospective cohort	ExRT versus RT	—	65 (39–82)	66 (44–88)	ExRT: 35 RT: 35	USA	24.8 (median value)	21.3 (median value)
Palmer <i>et al.</i> ⁴⁷	Retrospective cohort	ExRT versus RT	—	76 (72–82)	76 (68–86)	ExRT: 29 RT: 39	USA	30 (median value)	30 (median value)

ChRT, concurrent platinum-based chemotherapy plus radiotherapy; ExRT, concurrent cetuximab plus radiotherapy; HPV, human papillomavirus; NA, not available; RCT, randomized controlled trial; RT, radiotherapy.

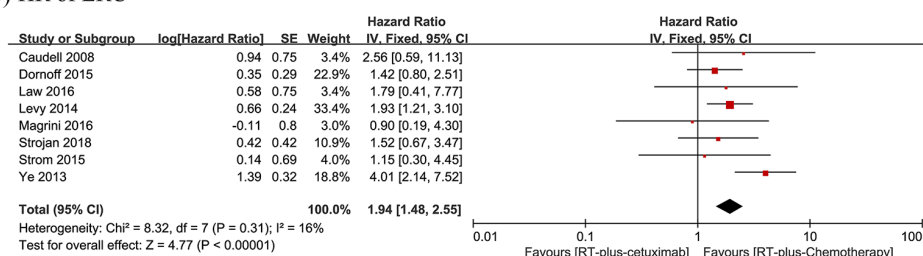
(A) HR of OS



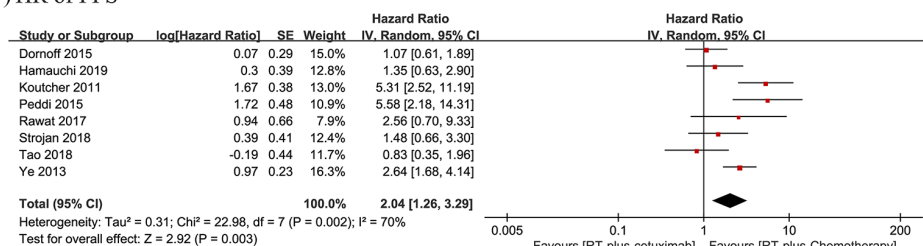
(B) HR of DSS



(C) HR of LRC



(D) HR of PFS



(E) HR of MFS

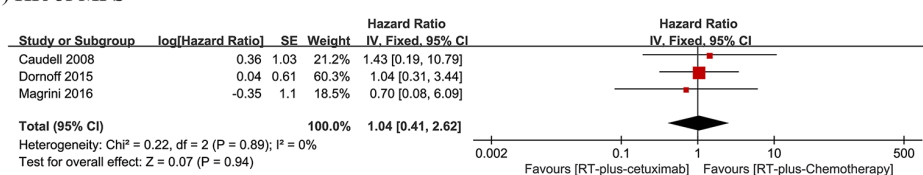


Figure 2. Forest plots comparing cetuximab plus concomitant radiotherapy with concurrent platinum-based chemotherapy plus radiotherapy in locally advanced head and neck squamous cell carcinoma. (A) Forest plot of hazard ratio (HR) for overall survival (OS). (B) Forest plot of HR for disease-specific survival (DSS). (C) Forest plot of HR for locoregional control (LRC). (D) Forest plot of HR for progression-free survival (PFS). (E) Forest plot of HR for metastasis-free survival (MFS). CI, confidence interval; IV, inverse variance; RT, radiotherapy.

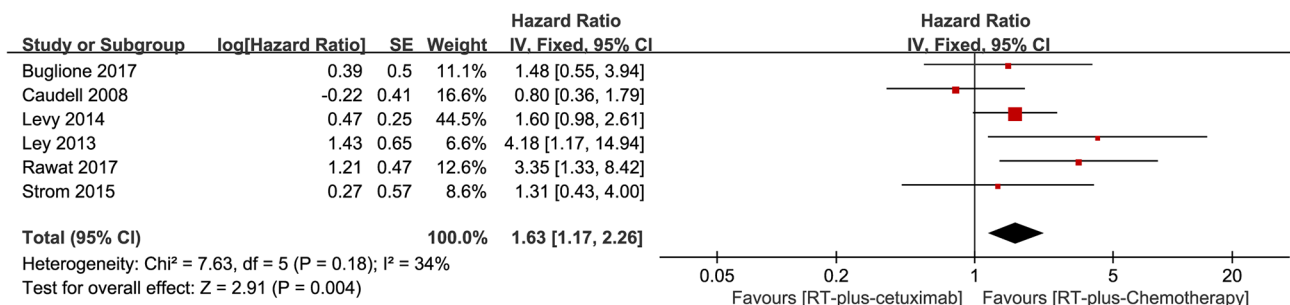


Figure 3. Multivariate analysis by Cox proportional hazards model on overall survival among patients with locally advanced head and neck squamous cell carcinoma receiving cetuximab plus concomitant radiotherapy *versus* concurrent platinum-based chemotherapy with radiotherapy.

CI, confidence interval; IV, inverse variance; RT, radiotherapy.

Survival outcomes of ExRT versus ChRT for HPV-positive locally advanced HNSCC patients

OS. HPV-positive oropharyngeal squamous cell carcinoma is considered to be a distinct disease entity from the HPV-negative ones. Three studies reported the OS of HPV-positive HNSCC patients receiving ExRT in contrast to ChRT, and the data were analyzed with a random-effects model according to the test of heterogeneity ($p = 0.07$; $I^2 = 62\%$). Results showed that the pooled HR of OS was 2.45 (95% CI: 0.95–6.32, $p = 0.06$; Figure 4A). The included three studies respectively reported an inferior OS in ExRT compared with ChRT. However, the OS in three studies was influenced by ExRT to different degrees, leading to varying HR values. Our study indicated that there existed an obvious trend of better OS in ChRT over ExRT for HPV-positive HNSCC patients, but no significant difference was observed here.

DSS. Three studies reported the DSS of HPV-positive HNSCC patients receiving ExRT in contrast to ChRT, and the data were analyzed with a fixed-effects model according to the test of heterogeneity ($p = 0.59$; $I^2 = 0\%$). Results showed that the pooled HR of LRC was 2.55 (95% CI: 1.27–5.12, $p = 0.009$; Figure 4B), indicating that ChRT achieved a significantly better DSS than did ExRT.

LRC. Three studies reported the LRC of HPV-positive HNSCC patients receiving ExRT in contrast to ChRT. Using a fixed-effects model according to the test of heterogeneity ($p = 0.14$; $I^2 = 49\%$), the pooled HR of LRC was 2.27 (95% CI: 1.52–3.38, $p < 0.0001$; Figure 4C), indicating that ChRT achieved a significantly better LRC than did ExRT in HPV-positive HNSCC patients.


Adverse events of ExRT versus non-CTX therapy

Out of all adverse events reported in the included studies, we retrieved 14 adverse events (grade ≥ 3) from studies comparing ExRT with non-CTX group (ChRT and RT). After combining the data from the included trials, we analyzed the RR for each event. The adverse events are listed in Table 2 according to the different organs involved, and the forest plot of each RR is shown in Figure 5. The results showed that the incidence of mucositis (RR: 1.17, 95% CI: 1.05–1.31, $p < 0.005$), skin toxicity (RR: 6.26, 95% CI: 4.55–8.62, $p < 0.00001$), and infection (RR: 2.27, 95% CI: 1.05–4.89, $p = 0.04$) were significantly higher in the ExRT group in contrast to the non-CTX group (ChRT and RT). The occurrence of anemia (RR: 0.35, 95% CI: 0.16–0.78, $p = 0.009$), leukocytopenia (RR: 0.17, 95% CI: 0.07–0.40, $p < 0.0001$), neutropenia (RR: 0.06, 95% CI: 0.02–0.21, $p < 0.0001$), nausea/vomiting (RR: 0.23, 95% CI: 0.12–0.47, $p < 0.0001$), and renal toxicity (RR: 0.14, 95% CI: 0.03–0.57, $p = 0.007$) were significantly associated with non-CTX therapy (ChRT and RT), rather than with ExRT.


Publication bias

The publication bias of the individual studies for locally advanced HNSCC patients was evaluated by funnel plots. By comparing ExRT with ChRT, the results showed that no obvious publication bias was observed in the funnel plots for the HR of OS (Figure 6A), HR of LRC (Figure 6B), HR of PFS (Figure 6C), and HR of OS based on multivariate analysis by Cox proportional hazards model (Figure 6D), for all p values were more

(A) HR of OS



(B) HR of DSS



(C) HR of LRC

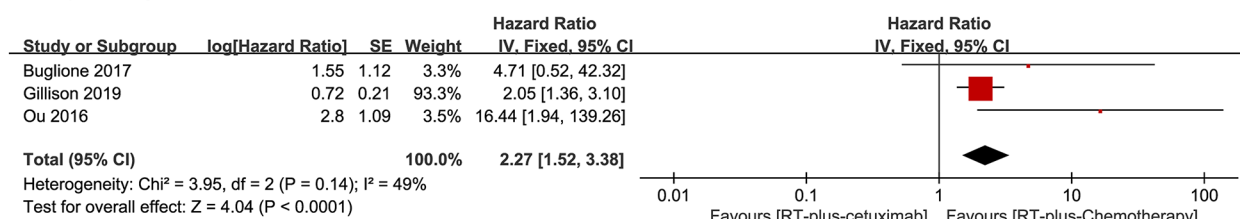


Figure 4. Forest plots comparing cetuximab plus concomitant radiotherapy with concurrent platinum-based chemotherapy plus radiotherapy in human papillomavirus-positive locally advanced head and neck squamous cell carcinoma patients. (A) Forest plot of hazard ratio (HR) for overall survival (OS). (B) Forest plot of HR for disease-specific survival (DSS). (C) Forest plot of HR for locoregional control (LRC).

than 0.05. This indicated that there exists no significant publication bias in the current survival outcomes between ExRT and ChRT for locally advanced HNSCC patients.

Discussion

This study was mainly focused on the comparison of clinical efficacy and safety between ExRT and ChRT in locally advanced HNSCC patients. Our results verified that in contrast to ChRT, ExRT was associated with worse survival outcomes including OS, DSS, LRC, and PFS for locally advanced HNSCC patients. Consistently, in HPV-positive HNSCC patient subgroups, ExRT showed inferior DSS and LRC to ChRT regimen. Furthermore, ExRT increased the incidence of mucositis, skin toxicity, and infection, and was associated with lower incidence of anemia, leukocytopenia, neutropenia, nausea/

vomiting, and renal toxicity in contrast to non-CTX therapies.

Chemotherapy improves survival in HNSCC patients. Decades ago, cisplatin had been utilized as a radiosensitizing agent concomitantly with RT.⁴⁸ A meta-analysis in 2009, which included 16,485 HNSCC patients from 87 randomized trials conducted between 1965 and 2000, demonstrated that chemotherapy concurrently with locoregional treatment (surgery and/or RT) significantly increased OS and achieved an absolute benefit of 4.5% at 5 years in contrast to locoregional therapy alone.⁴⁹ And in 2019 another meta-analysis, which including 5000 patients from 24 trials conducted between 1965 and 2000, reported that concurrent chemotherapy added to surgical locoregional treatment significantly improved OS, while induction chemotherapy did not increase OS.⁵⁰ Nowadays, ChRT, in which concurrent

Table 2. Toxicity grade ≥ 3 .

Toxicity	Studies included	Risk ratio	Cetuximab + events	Cetuximab + total	Cetuximab – events	Cetuximab – total
Mucositis	13	1.17 (1.05, 1.31)	310	648	425	1092
Xerostomia	3	1.87 (0.75, 4.63)	13	276	7	280
Skin toxicity	8	6.26 (4.55, 8.62)	255	702	106	1179
Anemia	7	0.35 (0.16, 0.78)	7	444	32	711
Thrombopenia	7	1.08 (0.49, 2.38)	11	215	17	419
Leukocytopenia	5	0.17 (0.07, 0.40)	7	126	48	204
Neutropenia	5	0.06 (0.02, 0.21)	0	181	68	405
Nausea/vomiting	5	0.23 (0.12, 0.47)	9	406	70	668
Dyspepsia	3	0.33 (0.03, 3.24)	76	324	83	343
Infection	5	2.27 (1.05, 4.89)	14	363	14	605
Pain	4	1.23 (0.70, 2.16)	25	319	31	463
Pulmonary toxicity	3	1.58 (0.42, 5.92)	4	268	4	366
Renal toxicity	3	0.14 (0.03, 0.57)	1	113	26	260
Dysphagia	5	0.94 (0.64, 1.36)	5	333	46	522

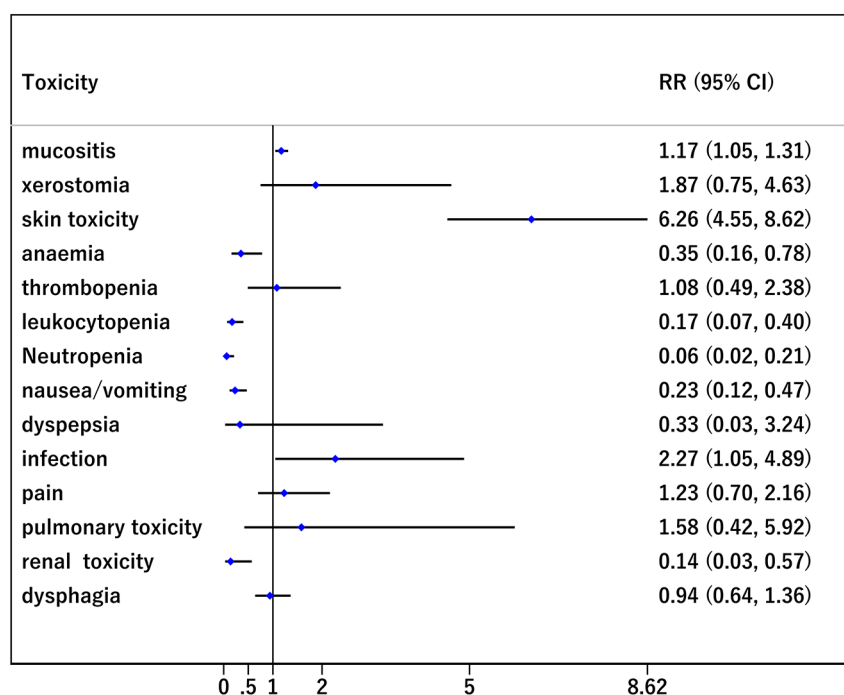


Figure 5. Forest plot of risk ratio of toxicities among patients with locally advanced head and neck squamous cell carcinoma receiving cetuximab plus concomitant radiotherapy *versus* non-cetuximab therapies [concurrent platinum-based chemotherapy plus radiotherapy and radiotherapy]. CI, confidence interval; RR, risk ratio

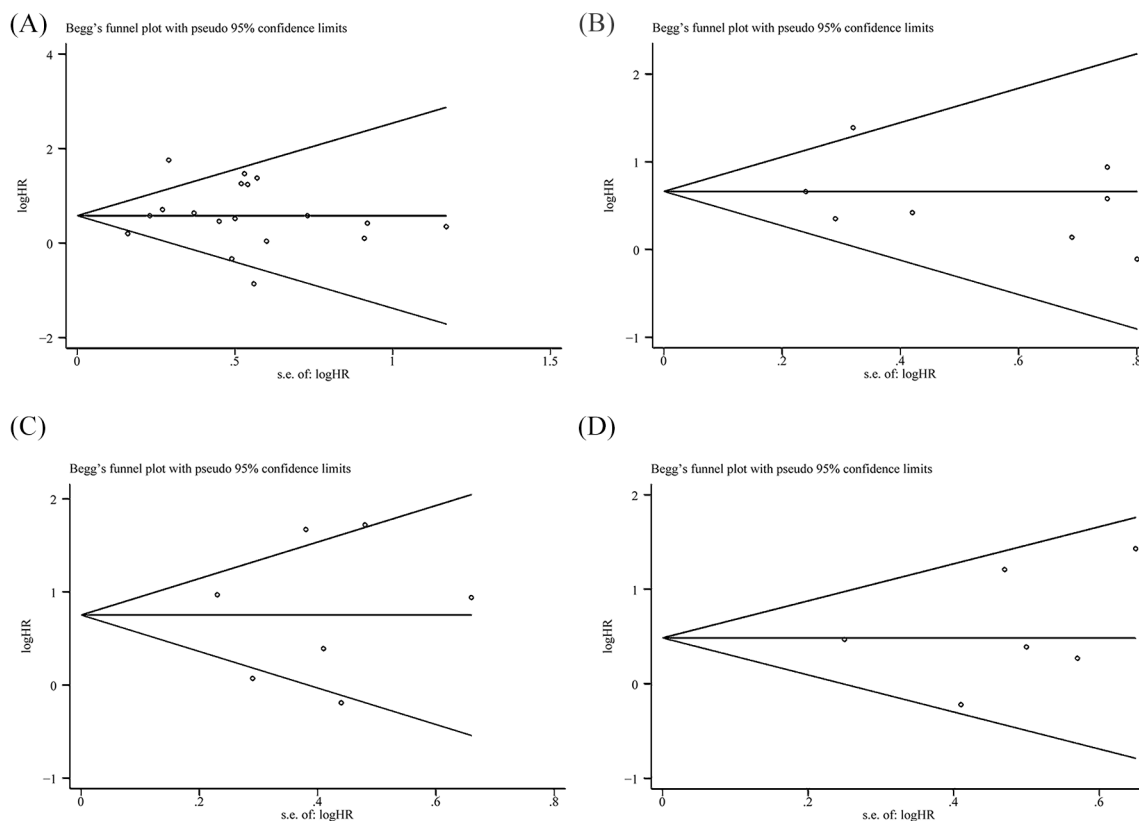


Figure 6. Begg's funnel plots among patients with locally advanced head and neck squamous cell carcinoma receiving cetuximab plus concomitant radiotherapy *versus* concurrent platinum-based chemotherapy plus radiotherapy. (A) Begg's funnel plot of hazard ratio (HR) for overall survival. (B) Begg's funnel plot of HR for locoregional control. (C) Begg's funnel plot of HR for progression-free survival. (D) Begg's funnel plot of multivariate analyses for overall survival.

platinum-based chemotherapy is performed with RT, remains the standard-of-care therapy for locally advanced HNSCC, and high-dose cisplatin ($100\text{mg}/\text{m}^2$) is recognized as the gold standard of radiosensitizer.¹⁴ High-dose cisplatin was associated with increased severe toxicities such as nephrotoxicity, hematologic toxicity, difficulty in swallowing, and requirement for a feeding tube. A previous study which included 230 patients receiving ChRT reported that 43% of assessable patients had severe late toxicities.⁷ Thus, the acute early and late toxic effects induced by platinum-based drugs, especially high-dose cisplatin, were limiting factors for its use and provided an impetus for seeking alternative strategies for radiation sensitization. Low-dose cisplatin was found to offer ease of administration and reduced toxicities,⁵¹ but no definite low-dose regimen was approved to be as effective as high-dose cisplatin therapy, and ongoing studies are investigating different low-dose regimens.⁵² Non-cisplatin regimens were proposed for vulnerable patients to avoid unbearable

toxicities from cisplatin, and the regimens were intended to be associated with the administration of carboplatin, docetaxel or paclitaxel, 5-fluorouraci, or the anti-EGFR drugs, especially CTX.⁵³

EGFR belongs to the ErbB family of tyrosine kinase receptors. The EGFR signaling pathway is involved in the tumorigenesis and progression of HNSCC,⁵⁴ and about 90% of HNSCC patients are detected overexpressing EGFR.^{55,56} CTX is a chimeric IgG1-subclass monoclonal antibody, which binds to the extracellular domain of EGFR with higher affinity than the natural ligand. It is the only approved targeted strategy for HNSCC patients.^{13,57} The binding of CTX to EGFR blocks the binding of a series of natural ligands, resulting in downregulation of the EGFR signaling cascade. RT-associated CTX decreases the capacity of DNA repair and inhibits tumor angiogenesis; meanwhile it facilitates apoptosis, sensitizes G1-phase cells to radiation, and reduces radioresistance of S-phase cells.⁵⁸⁻⁶⁰ In 2006, the trial by Bonner *et al.* initially

demonstrated an OS benefit when CTX was added to radiation in the treatment of locally advanced HNSCC, leading to acceptance of CTX-based combined modality therapy as a standard of care,¹³ and various other anti-EGFR agents such as panitumumab, zalutumumab, or gefitinib have failed to obtain notable clinical effect for HNSCC patients. Conflicting studies also existed such as the phase III RTOG 0522 trial, which demonstrated that the addition of CTX to cisplatin/radiotherapy did not achieve improved outcomes.⁶¹ In 2017, the Updated National Comprehensive Cancer Network guidelines for HNSCC reported that in locally advanced HNSCC, ChRT remains the standard treatment, and ExRT therapy is approved to be an effective and promising therapy regimen.⁶² The rationale was also demonstrated by a meta-analysis conducted by Tian *et al.* in 2018, which reported that anti-EGFR agents plus RT improved OS compared with RT in locally advanced HNSCC.⁶³ However, the evidence of ExRT superiority over ChRT was still lacking.

Increasing trials were performed to compare the efficacy of ExRT with the standard-of-care ChRT for locally advanced HNSCC patients. We searched the relevant trials and performed this study. As seen in Table 1, in most of the trials, ChRT involved the administration of cisplatin, and most of the trials included were non-RCT studies. The pooled analysis showed that in contrast to ChRT, ExRT was associated with worse survival outcomes including OS, DSS, LRC, and PFS. These data are consistent with a previous meta-analysis which showed that ChRT significantly improved OS, LRC, and PFS compared with ExRT for locally advanced HNSCC, and out of the 15 trials included in this meta-analysis, 13 trials utilized cisplatin as platinum-based chemotherapy drug.⁶⁴ Our results indicated that, so far, ExRT has failed to achieve better survival outcomes than ChRT for locally advanced HNSCC patients.

HPV-positive oropharyngeal cancer (OPC) is a unique entity among HNSCCs,⁶⁵ because HPV-positive OPC patients achieve better prognosis generally.⁶⁶ We then assessed the efficacy of ExRT compared with ChRT for HPV-positive HNSCC patients. The analysis included six trials which contained two RCTs, namely NRG Oncology RTOG 1016 and the European De-ESCALaTE.^{42,43} The ChRT in the six trials all involved the administration of cisplatin. Results showed that ExRT achieved inferior DSS and LRC in contrast to ChRT, and ExRT induced no significant difference in OS compared

with ChRT. A previous meta-analysis in 2019 included eight studies and, out of the trials, three were the same included trials as with our study, and they reported that in patients with HPV-positive HNSCC, ExRT was associated with inferior OS and LRC compared with ChRT, which to some extent was consistent with our findings.⁶⁷ To sum up, for locally advanced HPV-positive HNSCC patients, our results demonstrated that ChRT, especially the cisplatin-based RT, should remain the cornerstone of treatments.

For locally advanced HNSCC patients treated with the combination of CTX, adverse events (grade ≥ 3) were comprehensively analyzed in our study. The results showed that ExRT was associated with an increased risk of mucositis (RR: 1.17, 95% CI: 1.05–1.31, $p < 0.005$), skin toxicity (RR: 6.26, 95% CI: 4.55–8.62, $p < 0.00001$), and infection (RR: 2.27, 95% CI: 1.05–4.89, $p = 0.04$) compared with non-CTX therapies (ChRT and RT), while the occurrence of anemia, leukocytopenia, neutropenia, nausea/vomiting, and renal toxicity were significantly decreased in the ExRT group compared with the non-CTX group. These findings were partially consistent with a previous meta-analysis including 14,270 patients (a range of cancers including those of the colon, rectum, lung, and head and neck) from 25 RCTs, which demonstrated that CTX was significantly associated with high-grade skin rash and acne-like skin rash in contrast to a non-EGFR-monoantibodies group.⁶⁸ A systemic review which included 2152 HNSCC patients receiving ExRT from 48 studies determined the frequency of skin toxicity and reported that the mean rates of high-grade radiation dermatitis and acneiform rash were 32.5% and 13.4% respectively.⁶⁹ Although the incidence of skin toxicity is much higher in HNSCC patients receiving ExRT, many studies have demonstrated that skin toxicity is a treatable and reversible event that does not affect its clinical outcome.⁷⁰ In general, our results indicated that skin toxicity was the most common adverse event induced by ExRT therapy, while the patients receiving non-CTX therapies experienced a higher risk of more severe adverse events, including anemia, leukocytopenia, neutropenia, nausea/vomiting, and renal toxicity, suggesting that ExRT could substitute for ChRT in locally advanced HNSCC patients who were unable to tolerate cisplatin.

So far, there is no clear predictive marker which could determine that concurrent CTX is more

useful and tolerable in some populations of locally advanced HNSCC. Bonner reported that for the patients treated with CTX, OS was significantly improved in those who suffered an acneiform rash of grade ≥ 2 severity in contrast to the patients with no rash or grade 1 rash, but this adverse event could not be predicted prior to deciding the therapeutic regimen.⁴⁴ The potential markers such as EGFR mutations, HPV status, and performance status have not been validated to predict effectively or be adequately powered by significant differences in survival outcomes between the patient subsets.^{71,72} In 2019, a meta-analysis including 2653 HNSCC patients from five RCTs indicated that EGFR inhibition (three RCTs with CTX, one with gefitinib, and one with panitumumab) was associated with better OS in young patients than in older counterparts, and neither HPV status nor performance status had much effect on the relative OS benefit from EGFR inhibition.⁷² To determine the difference of survival outcomes between subsets which divided according to potential influencing factors, more prospective and RCT trials should be conducted in future, which would further help to find the most suitable patients to use CTX.

There are several limitations in our study. First, out of our included trials comparing survival outcomes between ExRT and ChRT, most included articles were non-RCT studies, so there would be statistically differences in patients' baseline. For instance, the patients in ExRT arms commonly had more pre-existing conditions, such as cardiac comorbidity, older age, and worse performance status, and obtained a higher Charlson Comorbidity Index,^{20,31} thus resulting in ExRT arms suffering from more severe systemic diseases. These could lead to heterogeneity between studies. More prospective trials and RCTs should be conducted in future. Second, since quality of life in locally advanced HNSCC patients has not been analyzed in our work, to identify the relation between CTX-induced toxicities with CTX-associated quality of life in future could help us in seeking methods to improve HNSCC patient compliance with CTX. Third, the cost-effectiveness of ExRT *versus* ChRT was not analyzed in our work, which also plays a vital role in determining the treatment strategy.

Conclusion

In conclusion, this study illustrated that in locally advanced HNSCC patients, CTX was an effective radiosensitizer, while ChRT achieved better survival

outcomes than ExRT. Moreover, in HPV-positive HNSCC patient subgroup, ExRT also obtained inferior survival outcomes in contrast to ChRT. ExRT is associated with a lower incidence of severe adverse events, including anemia, leukocytopenia, neutropenia, nausea/vomiting, and renal toxicity compared with non-CTX therapies, and the CTX-associated adverse events included mucositis, skin toxicity, and infection, which occurred more frequently in ExRT arms. It was demonstrated that ChRT should remain the first-line treatment for locally advanced HNSCC patients, and considering that some frail HNSCC patients were intolerable to severe toxicities induced by ChRT, ExRT could be an effective alternative treatment.

Acknowledgements

We thank Beijing Zhiyun Data Technology Co. LTD, for providing methodological advices.

Author contributions

Study concept and design: Mei Mei, Zhi-Yong Zhang, Xiao Zhang. Acquisition of data: Mei Mei, Yu-Huan Chen, Tian Meng. Analysis and interpretation of data: Mei Mei, Ling-Han Qu. Drafting of the manuscript: Mei Mei. Critical revision of the manuscript for important intellectual content: Mei Mei, Zhi-Yong Zhang, Xiao Zhang.

Conflict of interest statement

The authors declare that there is no conflict of interest.

Funding

The authors disclosed receipt of the following financial support for the research, authorship, and/or publication of this article: This work was funded by the National Natural Science Foundation of China (grant number 81700993), and is available via the SAGE Open Access.

ORCID iD

Yu-Huan Chen  <https://orcid.org/0000-0001-8280-0623>

Supplemental material

Supplemental material for this article is available online.

References

1. Bray F, Ferlay J, Soerjomataram I, *et al.* Global cancer statistics 2018: GLOBOCAN estimates of incidence and mortality worldwide for 36 cancers

- in 185 countries. *CA Cancer J Clin* 2018; 68: 394–424.
2. Pfister DG, Spencer S, Brizel DM, *et al.* Head and neck cancers, version 2.2014. Clinical practice guidelines in oncology. *J Natl Compr Canc Netw* 2014; 12: 1454–1487.
 3. Argiris A, Karamouzis MV, Raben D, *et al.* Head and neck cancer. *Lancet* 2008; 371: 1695–1709.
 4. Braakhuis BLM, Brakenhoff RH and Leemans CR. Treatment choice for locally advanced head and neck cancers on the basis of risk factors: biological risk factors. *Ann Oncol* 2012; 23(Suppl. 10): x173–x177.
 5. Chow LQM. Head and neck cancer. *N Engl J Med* 2020; 382: 60–72.
 6. Sindhu SK and Bauman JE. Current concepts in chemotherapy for head and neck cancer. *Oral Maxillofac Surg Clin North Am* 2019; 31: 145–154.
 7. Machtay M, Moughan J, Trotti A, *et al.* Factors associated with severe late toxicity after concurrent chemoradiation for locally advanced head and neck cancer: an RTOG analysis. *J Clin Oncol* 2008; 26: 3582–3589.
 8. Khalil MY, Grandis JR and Shin DM. Targeting epidermal growth factor receptor: novel therapeutics in the management of cancer. *Expert Rev Anticancer Ther* 2003; 3: 367–380.
 9. Chidharla A, Parsi M and Kasi A. Cetuximab. In: *StatPearls*. Treasure Island, FL: StatPearls Publishing, 2020.
 10. Pirker R, Pereira JR, Pawel JV, *et al.* EGFR expression as a predictor of survival for first-line chemotherapy plus cetuximab in patients with advanced non-small-cell lung cancer: analysis of data from the phase 3 FLEX study. *Lancet Oncol* 2012; 13: 33–42.
 11. Fornasier G, Francescon S and Baldo P. An update of efficacy and safety of cetuximab in metastatic colorectal cancer: a narrative review. *Adv Ther* 2018; 35: 1497–1509.
 12. Cohen RB. Current challenges and clinical investigations of epidermal growth factor receptor (EGFR)- and ErbB family-targeted agents in the treatment of head and neck squamous cell carcinoma (HNSCC). *Cancer Treat Rev* 2014; 40: 567–577.
 13. Bonner JA, Harari PM, Giralt J, *et al.* Radiotherapy plus cetuximab for squamous-cell carcinoma of the head and neck. *N Engl J Med* 2006; 354: 567–578.
 14. Wierzbicka M and Napierala J. Updated national comprehensive cancer network guidelines for treatment of head and neck cancers 2010–2017. *Otolaryngol Pol* 2017; 71: 1–6.
 15. Koutcher L, Sherman E, Fury M, *et al.* Concurrent cisplatin and radiation versus cetuximab and radiation for locally advanced head-and-neck cancer. *Int J Radiat Oncol Biol Phys* 2011; 81: 915–922.
 16. Ley J, Mehan P, Wildes TM, *et al.* Cisplatin versus cetuximab given concurrently with definitive radiation therapy for locally advanced head and neck squamous cell carcinoma. *Oncology* 2013; 85: 290–296.
 17. Peddi P, Shi R, Nair B, *et al.* Cisplatin, cetuximab, and radiation in locally advanced head and neck squamous cell cancer: a retrospective review. *Clin Med Insights Oncol* 2015; 9: 1–7.
 18. Ye AY, Hay JH, Laskin JJ, *et al.* Toxicity and outcomes in combined modality treatment of head and neck squamous cell carcinoma: cisplatin versus cetuximab. *J Cancer Res Ther* 2013; 9: 607–612.
 19. Strom TJ, Trotti AM, Kish J, *et al.* Comparison of every 3 week cisplatin or weekly cetuximab with concurrent radiotherapy for locally advanced head and neck cancer. *Oral Oncol* 2015; 51: 704–708.
 20. Huang J, Baschnagel AM, Chen P, *et al.* A matched-pair comparison of intensity-modulated radiation therapy with cetuximab versus intensity-modulated radiation therapy with platinum-based chemotherapy for locally advanced head neck cancer. *Int J Clin Oncol* 2014; 19: 240–246.
 21. Moher D, Liberati A, Tetzlaff J, *et al.* Preferred reporting items for systematic reviews and meta-analyses: the PRISMA statement. *PLoS Med* 2009; 6: e1000097.
 22. Peters JL, Sutton AJ, Jones DR, *et al.* Contour-enhanced meta-analysis funnel plots help distinguish publication bias from other causes of asymmetry. *J Clin Epidemiol* 2008; 61: 991–996.
 23. Shapiro LQ, Sherman EJ, Riaz N, *et al.* Efficacy of concurrent cetuximab vs. 5-fluorouracil/ carboplatin or high-dose cisplatin with intensity-modulated radiation therapy (IMRT) for locally-advanced head and neck cancer (LAHNSCC). *Oral Oncol* 2014; 50: 947–955.
 24. Strojjan P, Zakotnik B, Žumeret B, *et al.* Skin reaction to cetuximab as a criterion for treatment selection in head and neck cancer. *Anticancer Res* 2018; 38: 4213–4220.
 25. Tao Y, Faivre L, Laprie A, *et al.* Randomized trial comparing two methods of re-irradiation after salvage surgery in head and neck squamous

- cell carcinoma: once daily split-course radiotherapy with concomitant chemotherapy or twice daily radiotherapy with cetuximab. *Radiother Oncol* 2018; 128: 467–471.
26. Beijer YJ, Koopmanet M, Terhaard CHJ, *et al.* Outcome and toxicity of radiotherapy combined with chemotherapy or cetuximab for head and neck cancer: our experience in one hundred and twenty-five patients. *Clin Otolaryngol* 2013; 38: 69–74.
 27. Bibault JE, Morelle M, Perrier L, *et al.* Toxicity and efficacy of cetuximab associated with several modalities of IMRT for locally advanced head and neck cancer. *Cancer Radiother* 2016; 20: 357–361.
 28. Caudell JJ, Sawrie SM, Spencer SA, *et al.* Locoregionally advanced head and neck cancer treated with primary radiotherapy: a comparison of the addition of cetuximab or chemotherapy and the impact of protocol treatment. *Int J Radiat Oncol Biol Phys* 2008; 71: 676–681.
 29. Dornoff N, Weiß C, Rödel F, *et al.* Re-irradiation with cetuximab or cisplatin-based chemotherapy for recurrent squamous cell carcinoma of the head and neck. *Strahlenther Onkol* 2015; 191: 656–664.
 30. Hu M-H, Wang L-W, Lu H-J, *et al.* Cisplatin-based chemotherapy versus cetuximab in concurrent chemoradiotherapy for locally advanced head and neck cancer treatment. *Biomed Res Int* 2014; 2014: 904341.
 31. Levy A, Blanchard P, Bellefqih S, *et al.* Concurrent use of cisplatin or cetuximab with definitive radiotherapy for locally advanced head and neck squamous cell carcinomas. *Strahlenther Onkol* 2014; 190: 823–831.
 32. Magrini SM, Buglione M, Corvò R, *et al.* Cetuximab and radiotherapy versus cisplatin and radiotherapy for locally advanced head and neck cancer: a randomized phase II trial. *J Clin Oncol* 2016; 34: 427–435.
 33. Murakami N, Yoshimoto S, Matsumoto F, *et al.* Severe gastrointestinal bleeding in patients with locally advanced head and neck squamous cell carcinoma treated by concurrent radiotherapy and cetuximab. *J Cancer Res Clin Oncol* 2015; 141: 177–184.
 34. Onita B, Lester DRT, Iman AA, *et al.* Comparison of high-dose cisplatin-based chemoradiotherapy and cetuximab-based bioradiotherapy for p16-positive oropharyngeal squamous cell carcinoma in the context of revised HPV-based staging. *Rep Pract Oncol Radiother* 2018; 23: 451–457.
 35. Rawat S, Ahlawat P, Kakriaet A, *et al.* Comparison between weekly cisplatin-enhanced radiotherapy and cetuximab-enhanced radiotherapy in locally advanced head and neck cancer: first retrospective study in Asian population. *Asia Pac J Clin Oncol* 2017; 13: 195–203.
 36. Sakashita T, Homma A, Hatakeyama H, *et al.* Comparison of acute toxicities associated with cetuximab-based bioradiotherapy and platinum-based chemoradiotherapy for head and neck squamous cell carcinomas: a single-institution retrospective study in Japan. *Acta Otolaryngol* 2015; 135: 853–858.
 37. Law KS, Wong RKY, Yu E, *et al.* Treatment outcome of cetuximab compared with cisplatin during radical radiotherapy for locally advanced head and neck cancer. *Hong Kong J Radiol* 2016; 19: 96–102.
 38. Riaz N, Sherman E, Koutcher L, *et al.* Concurrent chemoradiotherapy with cisplatin versus cetuximab for squamous cell carcinoma of the head and neck. *Am J Clin Oncol* 2016; 39: 27–31.
 39. Ou D, Levy A, Blanchard P, *et al.* Concurrent chemoradiotherapy with cisplatin or cetuximab for locally advanced head and neck squamous cell carcinomas: does human papilloma virus play a role? *Oral Oncol* 2016; 59: 50–57.
 40. Buglione M, Maddalo M, Corvò R, *et al.* Subgroup analysis according to human papillomavirus status and tumor site of a randomized phase II trial comparing cetuximab and cisplatin combined with radiation therapy for locally advanced head and neck cancer. *Int J Radiat Oncol Biol Phys* 2017; 97: 462–472.
 41. Hamauchi S, Yokota T, Mizumachi T, *et al.* Safety and efficacy of concurrent carboplatin or cetuximab plus radiotherapy for locally advanced head and neck cancer patients ineligible for treatment with cisplatin. *Int J Clin Oncol* 2019; 24: 468–475.
 42. Gillison ML, Trotti AM, Harris J, *et al.* Radiotherapy plus cetuximab or cisplatin in human papillomavirus-positive oropharyngeal cancer (NRG Oncology RTOG 1016): a randomised, multicentre, non-inferiority trial. *Lancet* 2019; 393: 40–50.
 43. Mehanna H, Robinson M, Hartley A, *et al.* Radiotherapy plus cisplatin or cetuximab in low-risk human papillomavirus-positive oropharyngeal cancer (De-ESCALaTE HPV): an open-label randomised controlled phase 3 trial. *Lancet* 2019; 393: 51–60.
 44. Bonner JA, Harari PM, Giralt J, *et al.* Radiotherapy plus cetuximab for locoregionally advanced head and neck cancer: 5-year survival

- data from a phase 3 randomised trial, and relation between cetuximab-induced rash and survival. *Lancet Oncol* 2010; 11: 21–28.
45. Bonner JA, Giralt J, Harari PM, *et al.* Association of human papillomavirus and p16 status with mucositis and dysphagia for head and neck cancer patients treated with radiotherapy with or without cetuximab: assessment from a phase 3 registration trial. *Eur J Cancer* 2016; 64: 1–11.
 46. Heron DE, Rwigema JM, Gibson MK, *et al.* Concurrent cetuximab with stereotactic body radiotherapy for recurrent squamous cell carcinoma of the head and neck: a single institution matched case-control study. *Am J Clin Oncol* 2011; 34: 165–172.
 47. Palmer JD, Schneider CJ, Hockstein N, *et al.* Combination of post-operative radiotherapy and cetuximab for high-risk cutaneous squamous cell cancer of the head and neck: A propensity score analysis. *Oral Oncology* 2018; 78: 102–107.
 48. Leipzig B. Cisplatin sensitization to radiotherapy of squamous cell carcinomas of the head and neck. *Am J Surg* 1983; 146: 462–465.
 49. Pignon JP, Maître AL, Maillard E, *et al.* Meta-analysis of chemotherapy in head and neck cancer (MACH-NC): an update on 93 randomised trials and 17,346 patients. *Radiother Oncol* 2009; 92: 4–14.
 50. Dautzier E, Lacas B, Blanchard P, *et al.* Role of chemotherapy in 5000 patients with head and neck cancer treated by curative surgery: a subgroup analysis of the meta-analysis of chemotherapy in head and neck cancer. *Oral Oncol* 2019; 95: 106–114.
 51. Szturz P, Wouters K, Kiyota N, *et al.* Weekly low-dose versus three-weekly high-dose cisplatin for concurrent chemoradiation in locoregionally advanced non-nasopharyngeal head and neck cancer: a systematic review and meta-analysis of aggregate data. *Oncologist* 2017; 22: 1056–1066.
 52. Kunieda F, Kiyota N, Tahara M, *et al.* Randomized phase II/III trial of post-operative chemoradiotherapy comparing 3-weekly cisplatin with weekly cisplatin in high-risk patients with squamous cell carcinoma of head and neck: Japan Clinical Oncology Group Study (JCOG1008). *Jpn J Clin Oncol* 2014; 44: 770–774.
 53. Cramer JD, Burtness B, Le QT, *et al.* The changing therapeutic landscape of head and neck cancer. *Nat Rev Clin Oncol* 2019; 16: 669–683.
 54. Agulnik M. New approaches to EGFR inhibition for locally advanced or metastatic squamous cell carcinoma of the head and neck (SCCHN). *Med Oncol* 2012; 29: 2481–2491.
 55. Ang KK, Berkey BA, Tu X, *et al.* Impact of epidermal growth factor receptor expression on survival and pattern of relapse in patients with advanced head and neck carcinoma. *Cancer Res* 2002; 62: 7350–7356.
 56. Rubin Grandis J, Melhem MF, Gooding WE, *et al.* Levels of TGF- α and EGFR protein in head and neck squamous cell carcinoma and patient survival. *J Natl Cancer Inst* 1998; 90: 824–832.
 57. Vermorken JB, Mesia R, Rivera F, *et al.* Platinum-based chemotherapy plus cetuximab in head and neck cancer. *N Engl J Med* 2008; 359: 1116–1127.
 58. Vincenzi B, Schiavon G, Silletta M, *et al.* The biological properties of cetuximab. *Crit Rev Oncol Hematol* 2008; 68: 93–106.
 59. Gerber DE and Choy H. Cetuximab in combination therapy: from bench to clinic. *Cancer Metastasis Rev* 2010; 29: 171–180.
 60. Huang SM and Harari PM. Modulation of radiation response after epidermal growth factor receptor blockade in squamous cell carcinomas: inhibition of damage repair, cell cycle kinetics, and tumor angiogenesis. *Clin Cancer Res* 2000; 6: 2166–2174.
 61. Vermorken JB, Trigo J, Hitt R, *et al.* Open-label, uncontrolled, multicenter phase II study to evaluate the efficacy and toxicity of cetuximab as a single agent in patients with recurrent and/or metastatic squamous cell carcinoma of the head and neck who failed to respond to platinum-based therapy. *J Clin Oncol* 2007; 25: 2171–2177.
 62. Vermorken JB and Specenier P. Optimal treatment for recurrent/metastatic head and neck cancer. *Ann Oncol* 2010; 21: 252–261.
 63. Tian Y, Lin J, Tian Y, *et al.* Efficacy and safety of anti-EGFR agents administered concurrently with standard therapies for patients with head and neck squamous cell carcinoma: a systematic review and meta-analysis of randomized controlled trials. *Int J Cancer* 2018; 142: 2198–2206.
 64. Petrelli F, Coinu A, Riboldi V, *et al.* Concomitant platinum-based chemotherapy or cetuximab with radiotherapy for locally advanced head and neck cancer: a systematic review and meta-analysis of published studies. *Oral Oncol* 2014; 50: 1041–1048.
 65. Villa A and Hanna GJ. Human papillomavirus and oropharyngeal cancer. *Curr Probl Cancer* 2018; 42: 466–475.
 66. Fung N, Faraji F, Kang H, *et al.* The role of human papillomavirus on the prognosis and

- treatment of oropharyngeal carcinoma. *Cancer Metastasis Rev* 2017; 36: 449–461.
67. Sutton P, Skelin M, Rakusic Z, *et al.* Cisplatin-based chemoradiotherapy vs. Cetuximab-based bioradiotherapy for p16-positive oropharyngeal cancer: an updated meta-analysis including trials RTOG 1016 and De-ESCALaTE. *Eur Arch Otorhinolaryngol* 2019; 276: 1275–1281.
68. Qi WX, Sun YJ, Shen Z, *et al.* Risk of anti-EGFR monoclonal antibody-related skin rash: an up-to-date meta-analysis of 25 randomized controlled trials. *J Chemother* 2014; 26: 359–368.
69. Bonomo P, Loi M, Desideri I, *et al.* Incidence of skin toxicity in squamous cell carcinoma of the head and neck treated with radiotherapy and cetuximab: a systematic review. *Crit Rev Oncol Hematol* 2017; 120: 98–110.
70. Villavicencio M, Granados-García M, Vilajosana E, *et al.* Management of radiodermatitis associated with cetuximab in squamous cell carcinomas of the head and neck. *Int J Dermatol* 2017; 56: 602–609.
71. Licitra L, Störkel S, Kerr KM, *et al.* Predictive value of epidermal growth factor receptor expression for first-line chemotherapy plus cetuximab in patients with head and neck and colorectal cancer: analysis of data from the EXTREME and CRYSTAL studies. *Eur J Cancer* 2013; 49: 1161–1168.
72. Zhao Y, Liu W and Sun M. Impact of age on the overall survival benefits of anti-EGFR-containing regimens in head and neck squamous cell carcinoma: a meta-analysis of randomized controlled trials. *Crit Rev Oncol Hematol* 2019; 135: 39–46.